FGM news

EDITION 24 • 2022 • ISSN 2358-8888
JOINVILLE • SANTA CATARINA • BRASIL

LIVING THE FUTURE RIGHT NOW

GROWTH

Pioneering, innovation and leadership have always been part of our history. We know that new and promising horizons are part of our future.

Innovation has always been in our DNA and it has been this way since the beginning of the journey.

Throughout the years we have conquered the market, become leaders and crossed oceans taking innovation, quality, safety and reliability to more than 100 countries through Europe, Middle East, Asia, Latin and North America.

We aim at the best that the future may bring to the group and to dentistry. For that reason, we are excited with FGM's growth and expansion, which include the construction of a new plant, the introduction of new products and the opening of new markets around the world for a constant growth.

The inauguration of the new FGM Implants plant is planned for 2023 and it will be even bigger and follow a contemporary and technological concept. Besides the plant, we are also expanding the logistics center and carrying out the revitalization of the headquarters buildings.

All of this is to guarantee that our physical structure will be aligned with the present expansion moment and with the introduction of the brand in new countries and markets.

> *"Our main goal is to always offer the best service to our customers and partners and continue transforming smiles around the world."*

Thanks to the assertiveness of the company's business plan and to the quality of its products, FGM Implants, the group's implant division, has shown a substantial growth over the last years.

Present in more than 11 countries, with Latin America as its largest market, FGM Implants advances fast with negotiations in Europe, Middle East, Asia and Africa, markets with potential to surpass Latin America.

We are very proud of being a solid and committed company, a world reference in dental products. In 25 years, we have developed more than 400 products, fulfilling the commitment that motivates us: passion for dentistry.

Our search for improvement is consistent, with investments in research, technology and innovation, to offer our best to the market. Those efforts result in the high quality and performance of our products which are recognized internationally. One example is the Whiteness Perfect whitening gel (Wit Essential, in the United States), recognized in the United States by the publication Dental Advisor for three consecutive years and another is our resin cement Allcem Veneer APS, recognized for its high quality by the international publication Reality Ratings.

We are assured that our efforts in the expansion of the area of Implants and Biomaterials will consolidate FGM even more as the brand that transforms smiles. Pioneering, innovation and leadership have always been part of our history and with the increase in the physical space and the expansion of the brand, we know that new and promising horizons are going to be a part of our future. ■

Bianca Mittelstädt
Chief Executive Officer (CEO)

Friedrich Georg Mittelstädt
Chief Technical Officer (CTO)

Edward Mittelstädt
Managing Board

Artistic photographs: Dudu Medeiros

Whitening Solutions: **Scientifically-proven quality**

Innovation has been part of of FGM Dental Group's DNA, which began in the 90's with the development of the first dental whitening product for at-home use manufactured in Brazil, Whiteness Perfect. Before that product was introduced, all whitening gels commercialized in Brazil were imported.

Whiteness Line:

Leadership and high esthetics.

Get to know the complete line at:

It was the determination, the passion and the confidence of the couple Friedrich Georg Mittelstädt and Bianca Mittelstädt that resulted in a product that gained not only the confidence of the Brazilian market, where it is responsible for 85% of the share, but also crossed horizons and conquered more than 100 countries, being the leader in 15 of them.

Presently, Whiteness line is one of the most recognized and complete lines of whitening gels, a milestone that was only possible to achieve thanks to the investment and unstoppable effort by FGM in development and research. "Showing the quality and efficiency of a product by means of scientific confirmation is of incomparable value for FGM", says the CEO, Bianca Mittelstädt.

Hundreds of studies prove the quality and efficacy of the Whiteness line. The product creation and improvement process counts on the support of renowned professors and researchers from the dentistry community, who work for important universities and research centers in Brazil and abroad. That close relationship between FGM and the specialized academic community allows for the company to produce solutions that go beyond market's expectations.

Scientific Proof

Countless studies prove that the whitening gels made by FGM fulfill the result expectations in the best way possible. One of such studies is Effectiveness of dental bleaching in depth after using different bleaching agents published by PMC, by authros Dr. Maria D'Arce, Dr. Débora Lima, Dr Flávio Aguiar, Dr. Carlos Bertoldo, Dr. Gláucia Ambrosano and Dr. José Roberto Lovadino, who analyzed the different types of whiteners.

And the study: Long-term efficacy of in-office and at-home bleaching: a 2-year double-blind randomized clinical trial, published by PubMed, by researchers Dr. Lidia Yileng Tay, Dr. Carlos Kose, Dr. Daniel Rodrigo Herrera, Dr. Alessandra Reis and Dr. Alessandro Loguercio, which concluded that both whitening techniques – both in-the-office and at-home – demonstrated a whitening of the shade that was equivalent and relevant.

Many of the customers' questions can be resolved with comprehensive scientific resources. For example, the fact that the consumption of food with coloring and strong pigmentation does not affect the results of the treatment is proved in several studies. We can quote the study published by PubMed: Clinical effects of exposure to coffee during at-home vital bleaching, by researchers Dr. Alessandro Loguercio, Dr. Alessandra Reis, Dr. Márcia Rezende and Dr. Stella Kossatz.

Acess scientific abstracts about the Whiteness line. There are more than 100 articles.

"I am very proud to tell our patients that we can count on international quality products manufactured in Brazil with the credibility and scientific support that FGM provides."



Prof. Dr. Alexander Nishida

Master and doctor in biomaterials – USO | Professor of Aesthetic Dentistry courses



International recognition

The consistent investment in research has resulted in one more international recognition for Whiteness Perfect, which, for the second consecutive year, was mentioned by Dental Advisor, a publication that specializes in clinically evaluating dental products and serves as a reliable source for professionals all over the world.

Approved by the majority of the evaluators, the product stood out for the high acceptance from patients and for how easy it is to handle. According to the publication, Whiteness Perfect is efficient in what it is recommended for, with a soft and smooth texture, besides the great viscosity of the gel. Praised for its presentation and its whole system, the whitener was evaluated by 31 consultants and used by patients 242 times. "This recognition is the proof that we are in the right path," commented the CEO, Bianca Mittelstädt.

The characteristics of Whiteness Perfect were also recognized and the whitener was pointed out for containing potassium nitrate and sodium fluoride as desensitizing agents. Besides, the patients' satisfaction with the FGM product was also greater than the usual for the category.

Check the details of this award

"We have relied on the Whiteness line for many years for its quality and the excellent results obtained. When planning treatments in the University and in our courses, we always opt for individualized whitening treatments, respecting the particularities of each patient.

The Whiteness line by FGM offers a full range of products - both for in -office and supervised at-home whitening besides internal whitening and enamel stain removal. It offers different presentations, concentrations and compositions for dentists to effectively handle cases of color change.

No wonder Whiteness Perfect has been awarded by Dental Advisor, for the third consecutive year, as the best take-home whitening gel."

Prof. Dr. Thaís Thomé and Prof. Dr. Maria Carolina Erhardt

Does your patient have questions about tooth whitening?

Check the digital material we prepared and share it in your office.

30-year-old female patient.

CHIEF COMPLAINT:
Yellowish teeth.

TEETH WHITENING IN THE OFFICE: **A FAST AND EFFICIENT ALTERNATIVE FOR IMMEDIATE WHITENING**

Authors: **Dr. Luís Morgan, Dr. Rodrigo Albuquerque, Dr. Camila Caneschi and Dr. Janio Aquino**

INITIAL EVALUATION

During anamnesis, the patient reported her dissatisfaction with the color of her teeth for her upcoming wedding. In the clinical examination, it was observed that, according to the shade guide, her teeth were A2 and there would be a possibility to whiten them to satisfy the patient.

In face of her anxiety to have whiter teeth for her wedding, and the little time available for the procedure, the proposed treatment plan was to carry out a whitening session in the office with **Whiteness HP Automixx** (*FGM*), a whitening agent which contains 35% of hydrogen peroxide.

TREATMENT PERFORMED

To perform such whitening technique, before beginning the treatment, the prophylaxis was carried out, keeping the surface of the teeth to be whitened free of biofilm. The **ArcFlex** (*FGM*) lip retractor was used for the containment and protection of the lips, jugal mucosa and tongue. Next, the recording of the initial shade was done by means of the shade guide and photographic record of the smile, followed by the application of **Desensibilize KF 2%** desensitizer for 5 minutes. The product was removed with air and water jets. For the protection of the gingival tissue, the photoactivated **Top Dam Blue** (*FGM*) gingival barrier was used. With the operatory field prepared, the **Whiteness HP Automixx** (*FGM*) whitening agent was applied.

Initially, a small amount of the whitening gel was dispensed to guarantee the homogenization of the mixture using the specific tip that comes with the product and the gel was immediately applied over the dental surface so as to cover the whole vestibular face of the teeth with a fine layer, and was left on the teeth for 50 minutes, according to the manufacturer's recommendation.

The gel was moved around the surface of the teeth with the use of a disposable brush for the removal of possible air bubbles and for the renovation of the contact of the gel with the dental surface. The color of that type of whitening agent does not change in color with time when in contact with the teeth making it easier for the visual control of the product. Also, its pH is kept stable, without need to replace the gel. After 50 minutes, the gel was removed through aspiration followed by abundant washing of the teeth. The gingival barrier was removed with an exploratory probe and then, the **Desensibilize KF 2%** desensitizer was applied again for 5 minutes. Finally, polishing was carried out with **Diamond Flex** (*FGM*) felt disks and **Diamond Excel** (*FGM*) polishing paste. On the following day, after teeth hydration, the shade was recorded again as B1. The satisfactory result fulfilled the patient's expectations. ■

STEP-BY-STEP

Fig. 1 Initial aspect.

Fig. 2 Arc Flex (FGM) lip retractor in position.
Fig. 3 Shade selection before the whitening treatment.
Figs. 4, 5 and 6 Top dam Blue (FGM) gingival barrier and Whiteness HP AutoMixx (FGM) whitening gel applied, respectively.

Figs. 7 and 8 Application of the Desensibilize KF 2% (FGM) desensitizing agent.
Fig. 9 Final shade taking after the whitening treatment.
Fig. 10 Final aspect.

FGM MATERIALS USED

34-year-old female patient

CHIEF COMPLAINT
Very darkened teeth.

TOOTH WHITENING THROUGH THE COMBINED TECHNIQUE USING WHITENESS HP AUTOMIXX 6% AND WHITENESS PERFECT 16%: AN EFFECTIVE AND SAFE TECHNIQUE WITH EXCELLENT CLINICAL RESULTS

Authors: **Prof. Dr. João Cardoso Ferreira, Prof. Dr. Patrícia Teixeira Pires, Dr. Nuno Ribeiro Santos, Dr. Liliana Dias, Dr. Fabiana Almeida**

INITIAL EVALUATION

The patient came to the clinic to undergo a tooth whitening procedure because she was dissatisfied with the color of her teeth. No caries or dentin hypersensitivity were found in the clinical examination. Oral hygiene was good and the periodontium was clinically healthy.

TREATMENT PERFORMED

The proposed treatment plan was, after hygiene prophylaxis, tooth whitening – combined technique (one in-office session + at-home whitening). In a first consultation, the initial shade was taken (Figs. 1a and 1b) and molding was carried out with alginate for the manufacture of whitening trays. In the following appointment, the teeth were previously polished with a toothpaste and brush, and **Desensibilize KF 2%** was applied preventively for 10 minutes.

Then, to protect the soft tissues (lips, cheeks and tongue), the **Arcflex** retractor (*FGM*) was used and the gingival tissues were protected by applying a gingival barrier (**Top dam** – *FGM*) – Fig.2 . The 6% hydrogen-peroxide whitening gel (**Whiteness HP Automixx 6%** - *FGM*) was applied - maximum percentage allowed in Europe by directive 2011/84/EU - on all buccal surfaces from 2nd premolar to 2nd premolar in both arches – Fig. 3a and 3b.

The application time was 45 minutes in a single session, with the gel being activated for 5-5 minutes. After the action time, the gel was removed. Then, the teeth were polished with **Diamond Flex** disks (*FGM*) and **Diamond** felt disks (*FGM*) associated with **Diamond Excel** diamond paste (*FGM*). After polishing, **Fluor Care** fluoride foam (*FGM)* was applied. Immediately after the office session, the final shade was taken and desaturation was observed for A2 (Fig. 4).

The upper and lower whitening trays were then tested in the mouth. The carbamide peroxide gel **Whiteness Perfect 16%** (*FGM*) and the whitening trays were supplied to the patient with the following instructions for use: place one drop of gel per tooth in the molding tray in the deepest and most vestibular incisal area, position the molding tray and adapt it by pressing gently. Wear it overnight (about 8 hours/night) for a period of 2 weeks.

In the end, results were improved from A3.5 and A3 to A1 (fig. 5) without any complaints of dentin hypersensitivity or other undesirable effects, making the patient clearly satisfied. ■

STEP-BY-STEP

Figs. 1a and 1b INITIAL – Before whiteing. A3 – central incisives; A3,5 – canines (Vita shade guide)

Fig. 2 Application of the Top dam gingival barrier (FGM) in all papillae and cervical contour of teeth up to 1st molar.

Fig. 3a and 3b Application of Whiteness HP Automixx 6% hydrogen peroxide whitening gel on the buccal surface of the teeth.

Fig. 4 Result after the removal of Whiteness HP Automixx 6% whitening gel (FGM) with a change in color saturation.
Fig. 5 Final aspect– After 2 weeks - A1 (Vita shade guide).

CONCLUSION

The combined whitening technique using **Whiteness HP AutoMixx 6 %** and **Whiteness Perfect 16%** (*FGM*) provided excellent esthetic results and absence of dentin hypersensitivity, demonstrating efficacy and safety.

BIBLIOGRAPHY

1. ·**Marshall K, Berry TG, Woolum J. Tooth** whitening: current status. Compend Contin Educ Dent. 2010 Sep;31(7):486-92, 494-5; quiz 496, 508..
2. Pretty IA, Brunton P, Aminian A, Davies RM, Ellwood RP. Vital tooth bleaching in dental practice: 3. Biological, dental and legal issues. Dent Update. 2006 Sep;33(7):422-4, 427-8, 431-2.

FGM MATERIALS USED

31-year-old male patient.

CHIEF COMPLAINT:
Dissatisfaction with the yellowish shade of his teeth.

WHITENING OF VITAL TEETH
WITH WHITE CLASS AT 7.5%

Author: **Dr. Luís Henrique Fischer**

INITIAL EVALUATION

After detailed anamnesis and clinical exam, the professional noted good periodontal health and normal aspect of the oral mucosa and absence of cavity lesions.

TREATMENT PERFORMED

Initially, the shade of the upper incisive (A3.5) and canine (A4) teeth was taken according to the Vita shade guide, with subsequent photographic recording. The prophylaxis was done with ultrasound, sodium bicarbonate and pumice paste. Next, the molding of the arches was made with alginate and the plaster model was obtained for posterior manufacture of the dental whitening trays using the **Whiteness** plates (5.0x1.0mm). The whitener of choice was **White Class** at 7.5% inside the molding trays in the vestibular faces of the teeth to be whitened.

The recommendation was to use the whitening gel for 45 minutes per day with weekly follow-up appointments. The first follow-up was carried out after one week of treatment when the whitening to the shade Vita A2 was noted. In the second follow-up appointment, 14 days after the beginning, the patient reported no sensitivity, no incident or discomfort. 21 days after the start, the final shade observed was B1 both for central incisive and canine teeth. The at-home whitening proved excellent efficacy and absence of sensitivity, providing satisfaction and comfort for the patient. ■

PASSO A PASSO


1a


1b


1c


2

Figs. 1a to 1c Initial aspect of the smile, frontal smile and with retracted lips, retracted lips with shade taking: A3.5 (Vita).
Fig. 2 Dental aspect at the 7-day follow-up appointment: A2 (Vita).
Figs. 3a to 3c Final aspect of the smile, frontal smile and shade taking B1 (Vita). Smile and retracted lips, shade taking: B1 (Vita).


3a


3b


3c

FGM MATERIALS USED

Whiteness | #1

LEADERSHIP AND HIGH ESTHETICS LIKE NO OTHER

DA 2020 TOP AWARD WINNER

DA 2021 TOP AWARD WINNER

DA 2022 TOP AWARD WINNER

More than 6000 Whiteness TREATMENTS PER DAY IN THE WORLD

FGM DENTAL GROUP

"The Whiteness line is simply complete. Different applications, concentrations and active agents are available for treatments at home, in the office and for devitalized teeth. And what stands out: ***it is extensively researched through randomized clinical trials which confirm its efficacy and safety.***

Prof. Dr. Alessandra Reis
Doctor in Dental Material from the Universidade of São Paulo - São Paulo
Professor of graduation and post graduation levels at the Universidade Estadual de Ponta Grossa - Paraná | CNPq level 1B researcher

34-year-old male patient.

CHIEF COMPLAINT:
Change in color of tooth 21 due to a trauma and endodontic treatment.

HARMONIZING SMILES **WITH DENTAL WHITENING AND DIRECT VENEERS IN COMPOSITE**

Authors: **Dr. Leonardo Buso and Dr. Giovana Ribeiro Martins Buso**
Artistic photographs: **Dudu Medeiros**

INITIAL EVALUATION

During the initial evaluation, the patient reported that he was dissatisfied with the strong darkening of tooth 21 due to a trauma in his adolescence and the fracture of the incisal edge (Figures 1-5). We also noted that all teeth had a more saturated shade, around A3 or A3.5 in the Chromascope scale (Figure 6), which made us recommend the at-home whitening treatment.

TREATMENT PERFORMED

At our clinic, we always choose the most conservative treatments, so in this clinical case, we decided to carry out the internal whitening of tooth 21 before planning restorations for esthetic reasons. In the first step, the cleaning was carried out with an ultrasound equipment, followed by sodium bicarbonate jets, dental polishing and hygiene instructions including the correct brushing techniques and the use of dental floss to maintain buccal health.

In the endodontic evaluation x-rays, the professionals noted that the filling in element 21 was not satisfactory (Figure 7). A re-treatment was recommended for better cleaning and radicular sealing (Figure 8). A cervical plug following the recommendations of the scientific literature was made with composite to begin the internal whitening with *FGM* **Whiteness Perborato** following the recommendations of the manufacturer. Three sessions were carried out with an interval of 4 days between them.

Minor shade improvement was obtained but the patient would still begin the whitening with a molding tray of both upper and lower arches. Models were obtained by means of irreversible hydrocolloid for the making of the individual molding trays with 1mm thick vinyl plates (**Whiteness**, *FGM*). The plates were cut approximately 1.5mm above the gingival margin, and tested for fitting and comfort.

No type of relief was made during the forming of the plate in a vacuum equipment. We decided to carry out the at-home whitening treatment with 16% Carbamide Peroxide (**Whiteness Perfect**, *FGM*) for three weeks with the use for 2 to 3 hours per day, following the recommendations of the manufacturer. At the end of three weeks, the patient was satisfied with the shade obtained, however, the vital teeth got whiter than the non-vital one (Figures 9 and 10), giving evidence to a more yellowish tone in the non-vital tooth.

We decided not to carry out another attempt of an internal whitening. The choice was to make a direct veneer with composite, which fulfilled the patient's expectations (Figure 11). The direct veneer in composite was done 20 days after the end of the whitening treatment. The preparation measured 1.5mm approximately. The finishing and polishing were carried out in a second session. In the final photographs (Figures 12 and 13) it is possible to see that a harmony of the smile was achieved with conservative whitening treatments and a direct veneer in composite of one single element. ■

STEP-BY-STEP



Figs. 1, 2 and 3 Initial smile of the patient with frontal, right side and left side views. According to the photography protocol, it is possible to note teeth with a high saturation and a central incisive with a strong color change due to the endodontic treatment.

Fig. 4 Internal view of the arches. Note the presence of tartar build-up (poor oral hygiene, needing preliminary procedures before the esthetic treatment) and highly saturated teeth color. | **Fig. 5** Close up view of the upper teeth where we note that tooth 11 shows a lighter shade which is very different when compared to posterior teeth and to tooth 21. The whitening strategy must be careful in order to achieve the maximum final balance. | **Fig. 6** Shade selection with the Chromoscope scale after prophylaxis. Teeth with darker saturation (A3 and A3.5). It is important to position the scale correctly to take the shade.

Fig. 7 Initial x-rays showing that the endodontic treatment was not satisfactory.
Fig. 8 Final x-rays after the endodontic treatment, now with the correct radical and apical sealing. At this moment, the restorative material was removed approximately 3mm below the junction of the cement and the enamel for the making of the "plug" with composite to begin the attempt for the internal whitening.

Figs. 9 and 10 Smile and internal view of the teeth after the internal whitening and at-home whitening following the protocol. At first, we thought that the result obtained with the internal whitening would be satisfactory, but, after the at-home whitening with molding trays, the non-vital tooth was still much more saturated than the others which led to the choice for the making of a direct restoration in composite.
Fig. 11 Direct veneer finalized and after the finishing and polishing session with a little bleeding at the margin. The naturality was achieved with direct composite.

Figs. 12 and 13 Final photos of the face with the patient happy with the results. The objectives were reached with naturality, maintaining the uniqueness of the smile, with a conservative treatment.

FGM MATERIALS USED

36-year-old male patient.

CHIEF COMPLAINT:
Dissatisfaction with the smile and worry about the shape of the upper teeth.

ALLCEM VENEER APS FOR **MAKING MINIMALLY INVASIVE VENEERS**

Authors: **Dr. Leonardo Fernandes da Cunha, Dr. Ana Carolina Portes Pasmadjian, Dr. Carlos Maranghello, Dr. Gabriella Resende Allig and Dr. Vitória Beatriz Souza da Silva**

INITIAL EVALUATION

After the radiographic images and the clinical exam, the professionals noted dental wear.

TREATMENT PERFORMED

The initial prophylaxis was followed by the development of the molding trays for the at-home whitening, to be carried out for four weeks with *FGM* **Whiteness Perfect** 10% carbamide peroxide. The restorations in wax were made in order to define the shape and size of the teeth as well as to help plan the treatment.

Next, the shade was selected. After waxing, an addition reaction silicone mold was made and filled with the bis-acryl composite **PrimmaArt** by *FGM* with pressure until the reaction of the material had finished. The mock-up procedure is a reliable tool of communication between the patient and the dentist and technician.

The teeth approved by the patient were ready to be prepared. In the molding, retraction cords and addition silicone were used. After the development of the temporary restorations, the patient wore them for a few days to test the planned restorative treatment. The ceramic veneers for the restorations were manufactured and approved after the fitting and shade takings.

The product used for the adequate selection of the cement shade was the **Allcem Veneer Try-In** paste in the E-Bleach shade. The veneers were washed for the removal of the test paste and dried with air. The internal surfaces were etched with hydrofluoric acid 5% **Condac Porcelana** for 20 seconds with running water and dried with an air syringe. Then they were silanized with Prosil and dried for 60 seconds.

That was followed by the application of the adhesive. The same adhesive system was applied to the surface of the teeth. The restoration was bonded with the *FGM* **Allcem Veneer APS** light-curing cement, and then the veneers were carefully placed over the teeth. The excess cement was removed from the gums and polymerization was carried out for 120 seconds on each tooth. ■

STEP-BY-STEP

Figs. 1a and 1b Close up view of the front (A) and side (B) of the anterior teeth showing the wear.

Fig. 2 After the at- home whitening treatment with Whiteness Perfect 10% (FGM).

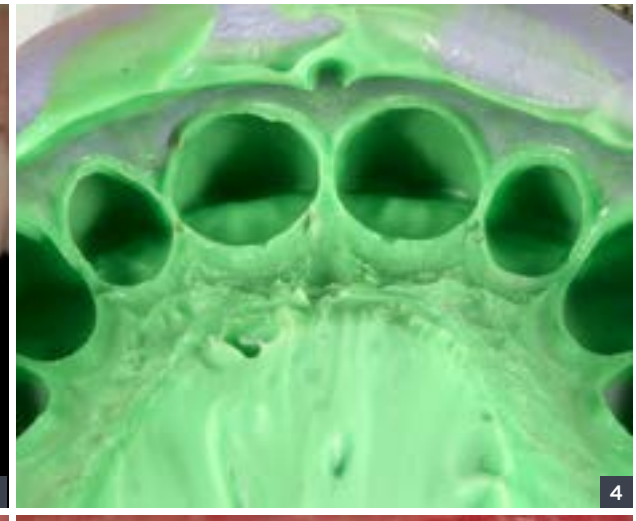

Fig. 3 Diagnostic waxing. | **Fig. 4** Mold. | **Figs. 5a and 5b** Close up photographs of the final restorations.

CONCLUSION

The use of reliable cementation materials in the application of ceramics may avoid unpredictable results. The cementation procedure with photoactivated cements is a method that offers predictability to the restorative treatment. Therefore, this clinical report demonstrates a treatment accurately performed with ceramic veneers with minimum thickness.

Rehabilitating esthetic dentistry must be carried out in the most predictable way[1]. Thus, the restorative treatment is essential for the obtainment of the functional and esthetic treatment. In the cases of functional and esthetic rehabilitation, the desired result of the treatment must be reached by means of meticulous diagnostics and execution. A study model is crucial for the success of the treatment.[2]

After the planning procedure -waxing and mock-up - the minimally invasive dentistry must be used whenever possible. The minimum thickness veneers have excellent properties in the long term and low failure rates[3]. Finally, the cementation step is critical for the longevity of the treatment. A quality photoactivated cement with easy flow and excess removal makes it easier for the execution and for the obtainment of successful results.

That way, the materials for this step must be carefully selected. Therefore, this work shows that the cementation carried out with quality materials may facilitate the work of the dentist and allow for a conservative and esthetic treatment. ■

REFERENCES

1. Reshad M, Cascione D, Magne P. Diagnostic mock-ups as an objective tool for predictable outcomes with porcelain laminate veneers in esthetically demanding patients: a clinical report. J Prosthet Dent 2008;99:333–339.

2. da Cunha LF, Reis R, Santana L, Romanini JC, Carvalho RM, Furuse AY. Ceramic veneers with minimum preparation. Eur J Dent 2013;7:492–496.

3. Layton DM, Clarke M, Walton TR. A systematic review and meta-analysis of the survival of feldspathic porcelain veneers over 5 and 10 years. Int J Prosthodont 2012;25:590–603.

FGM MATERIALS USED

24-year-old female patient.

CHIEF COMPLAINT:
Patient was not satisfied with the esthetic of her smile, especially with the color of her teeth.

WHITENING OF VITAL TEETH

Author: **Dr. Maristela Lobo**
Artistic Photographs: **Dudu Medeiros**

INITIAL EVALUATION

After the anamnesis, photographs and detailed clinical exam, the systemic and buccal health of the patient was confirmed, without any signs of oral pathologies.

TREATMENT PERFORMED

After prophylaxis with ultrasound and sodium bicarbonate jets, and pumice paste, the shade of the teeth was taken and photographed: A 3 for the anterior upper teeth and A3.5 for the upper canine, when compared to the Vita shade guide. Then, the molding of the two arches was carried out with alginate to poroduce the plaster models. Over those models, 1.0 mm thick silicone molding trays were manufactured (**Whiteness** *FGM*). The molding trays were cut 1mm above the gingival level and fitted to check their correct adaptation, retention and comfort. After the fitting of the molding trays, the patient was instructed to apply a small drop of carbamide peroxide at 22% (**Whiteness Perfect 22%** *FGM*) on the vestibular faces of the teeth to be whitened. The recommendation was to wear the tray for 1 hour per day, during 14 days, at night. The patient was monitored weekly and at the end of the treatment, the shades were assessed. The final shade achieved was BL4 for the central incisive teeth and B1 for the canine. The at-home whitening demonstrated an excellent efficacy and absence of sensitivity, bringing satisfaction and comfort to the patient. ■

STEP BY STEP

Figs. 1a, 1b and 1c Initial aspect: frontal photo, frontal smile and retracted lips.

Figs. 2a Zoom in of the smile. | **Fig. 2b** Right side with retracted lips. | **Fig. 2 c** Left side with retracted lips.

Figs. 3a, 3b and 3c Upper arch with black contrast. Shade recorded: A3 for upper incisive teeth and A3.5 for upper canine (Vita shade guide).

Figs. 4a, 4b and 4c Final shade achieved: BL4. Brighter teeth with high value.

Figs. 5a, 5b and 5c Final aspect: frontal photograph, frontal smile and retracted lips.

FGM MATERIALS USED:

WHITENESS PERFECT

Carbamide peroxide whitening gel at 10%, 16% and 22% for supervised at-home use.

3x TOP AWARD WINNER

ELECTED FOR THE THIRD CONSECUTIVE YEAR THE BEST TAKE-HOME WHITENING GEL BY DENTAL ADVISOR.

Complete kits with tray plates and tray cases.

- Best desensitizing package: potassium nitrate + sodium fluoride.
- Excellent viscosity: easy to apply and handle.
- pH close to neutral: prevents demineralization of the enamel and dentin.
- High yield: each syringe of 3g yields up to 9 applications.


FGM
DENTAL GROUP
Whiteness Perfect
16%
38
DA
DENTAL ADVISOR
2022
TOP AWARD
WINNER
DA
DENTAL ADVISOR
2021
TOP AWARD
WINNER
DA
2020
TOP AWARD
WINNER

22-year-old female patient.

CHIEF COMPLAINT:
Dissatisfaction with the color and shape of her incisive teeth.

DIRECT VENEERS IN COMPOSITE: **FUNCTIONALITY AND ESTHETICS WITHOUT DENTAL ABRASION**

Authors: **Dr. Pedro Jader Agostinho Macêdo and Dr. Vanessa Kelly Rodrigues Tavares Macêdo**

INITIAL EVALUATION

During the initial clinical exam, the professionals noticed the presence of a diastema between the central incisive teeth, incisal wear on the upper canine and incisive teeth and lack of a canine guidance in the laterality movements. During shade taking, an A3 predominant shade was noted (Vita Classical shade guide) compromising the esthetics and affecting the patient's emotional state – she was ashamed of her smile.

TREATMENT PERFORMED

The treatment plan consisted of the combined dental whitening treatment, with two immediate whitening sessions with **Whiteness HP 35%** (*FGM*). Then, the molding of the arches in alginate and the making of 1-mm thick silicone molding trays were carried out with **Whiteness** (*FGM*) and a vacuum forming machine. The patient was instructed to apply a small drop of 10% carbamide peroxide – **Whiteness Perfect 10%** (*FGM*) – on the vestibular faces of the teeth to be whitened and wear the molding tray with the gel for an hour per day, during 8 days.

The combined whitening treatment demonstrated excellent efficacy and lack of sensitivity, bringing satisfaction and comfort to the patient and a predominantly A1 final shade.

To obtain improvement in dental shape and proportions and in order to close the central diastema, we used digital scanning and molding (Exocad), through which we had the possibility of overlapping the models (tridimensional) with the photographs (bidimensional), allowing for the design of a customized smile, taking into account the patient's smile and face.

After molding, we transfer the plan to the mouth of the patient by means of temporary pieces through the mock-up technique, making it possible for the patient to visualize and approve the shape of their future smile even before beginning the treatment. That way, the patient becomes the co-author of her future smile, being able to give her opinion about the shape of her teeth during the temporary phase, guaranteeing predictability to the treatment.

We decided together to make veneers for 6 teeth (from upper canine to upper canine) to obtain an excellent harmony for the smile, as well as providing the canine guidance for the patient.

The material chosen for the veneers was the composite resin, because in this specific case, it has the advantage of allowing for additive direct veneers, without any need to abrade the dental structure, which is an excellent rehabilitation option for young patients.

The composite chosen was **Vittra APS** (*FGM*) for its capacity to promote and maintain an extremely polished surface in the long term.

The polishing was carried out with the disks from the **Diamond Master** (*FGM*) kit. ■

STEP-BY-STEP

Fig. 1 Initial aspect - smile. | **Fig. 2** Initial aspect – face.

Fig. 3 Digital Modeling. | **Fig. 4** Whitening with Whiteness HP (FGM).

Figs. 5 Isolation of the site, gingival retraction, and palatal wall for direct veneers.
Fig. 6 Polishing with Diamond Flex FGM disks.
Fig. 7 Final aspect – frontal view.
Fig. 8 Final aspect – side view.

Fig. 9 Re-establishing the canine teeth.
Fig. 10 Before and after - frontal smile.
Fig. 11 Before and after - face.

FGM MATERIALS USED

21-year-old female patient.

CHIEF COMPLAINT:
Dissatisfaction with the color of the teeth, specially tooth 11.

DIRECT VENEERS ON SINGLE INCISIVE TOOTH ASSOCIATING WHITENING AND DIRECT VENEER WITH VITTRA APS

Author: **Dr. Fábio Sene**

INITIAL EVALUATION

After the clinical exam, it was noted that tooth 11 had minor color and shape alteration, due to an old composite veneer.

TREATMENT PERFORMED

The patient sought for treatment because she was not satisfied with her tooth 11, which had undergone a previous attempt of remodeling with composite. She also wanted to whiten the other teeth. All the possible techniques were explained to the patient who decided to undergo whitening sessions in the office at first, and then have a veneer made in composite for her tooth 11. Two whitening sessions were carried out.

The first was done with **Whiteness HP Maxx**, in two 15-minute applications in the first session and then, a week later, the second session used **Whiteness HP Automixx** for 45 minutes. Three weeks after the whitening, a chromatic map of the tooth was done and the shade was chosen for the **Vittra APS** composite. Note the great number of optical effects to be reproduced from tooth 21 and the huge challenge that is to make one single central incisive.

In the following session, the old composite was removed and a conservative preparation for the veneer was done only on the enamel of tooth 11. After the absolute isolation and the adhesive technique: etching with **CONDAC 37%** for 15 seconds and application of the **Ambar Universal APS** adhesive system, the making of the veneer began with the application of the composite DA1 on the cervical part of the tooth and of the composite DA0 in the medium and incisal areas.

Next, the composite **Trans OPL** was used to emphasize the characteristics of translucency and opalescence of the incisal area. To finalize, the professional applied the enamel composite E-Bleach, defining the whole vestibular anatomy. The initial finishing of the veneer was carried out, refining the shape and anatomy and the patient was released. 15 days later, the patient returned for control and shade-taking, final shine and polishing. In this highly challenging case, in which we needed to mimic a single incisive tooth, an excellent result was reached through the association of those techniques and the excellent chromatic effect obtained with the **Vittra APS** composite. ■

STEP-BY-STEP

Fig. 1 Smile showing tooth 11 with alterations in color and shape. | **Fig. 2a** Chromatic and anatomic detail of the teeth. | **Fig. 2b** Chromatic and anatomic detail of the teeth with lingual interposition.

Fig. 3a Application of Top dam for a first whitening session in the office. | **Figs. 3b and 3c** Application of the Whiteness HP Maxx whitening gel for the first session. | **Fig. 3d** Color change of the gel during the whitening. | **Fig. 3e** Result after the first application of the gel for 15 minutes. | **Fig. 3f** Result of a second application of the gel for 15 minutes. | **Fig. 3g** Result of the first application one week later. | **Fig. 3h** Smile showing the result of the first application one week later.

Fig. 4a Application of Top dam for the second whitening session in the office. | **Fig. 4b** Easy application of the gel with the self-mixing tip. **Fig. 4c** Application of the gel to all the teeth. | **Fig. 4d** Result after a 50-minute application of the gel.

Fig. 5a Chromatic mapping and shade selection for the Vittra APS composite (Detail Fig. 5b).
Fig. 6 Absolute isolation.



Fig. 7a Acid etching of the dental substrate with Condac 37.
Fig. 7b Use of the Ambar Univesal APS adhesive system.
Fig. 7c Application of Ambar Univeral APS. Note how light the adhesive is because of the APS technology.

Fig. 8a Vittra APS DA1 composite, used in the cervical area.
Fig. 8b Cervical application of the composite.
Fig. 8c Cervical anatomy made with DA1.
Fig. 8d Vittra APS DA0 composite used in the medium and incisal thirds.
Fig. 8e Careful application of the composite, respecting the dental anatomy.
Fig. 8f Detail of the whole dentin portion made with the stratification and anatomic details.
Fig. 8g Front view of the dentin made.

Fig. 8h Vittra Trans OPL used in the incisal region. | **Fig. 8i** Trans OPL composite applied in the incisal area, between the lobes, to point out the opalescence of the region. | **Fig. 8j** Proximal view of the application of the Trans OPL composite. | **Fig. 8l** Cervical view showing the whole anatomy and stratification obtained. | **Fig. 8m** Frontal view of the stratification. | **Fig. 8n** E-bleach enamel used for the finalization of the veneer. | **Fig. 8o** Application of the composite. | **Fig. 8p** Use of a light-colored brush to facilitate the distribution of the composite. | **Fig. 8q** Finalized enamel.

Fig. 9a Incisal check and finishing with Diamond Pro disk.
Fig. 9b Removal of accesses, cervical region finishing with a 3195F diamond tip.
Fig. 9c Cervical black triangle finishing with a number 12 scalpel blade.
Fig. 9d Immediate result after the initial finishing.

Fig. 10a Final result after finishing and polishing.
Fig. 10b Distal view.
Fig. 10c Mesial view.
Fig. 10d View from top to top. Note the beautiful anatomy and incisal translucency obtained.
Fig. 10e View from top to top. Note the beautiful anatomy and incisal translucency obtained.

Figs. 11a and 11b Front view of the smile. Note the great whitening effect and the excellent naturality and the obtained esthetic result.

FGM MATERIALS USED

WHITENESS HP AUTOMIXX

Hydrogen peroxide whitening gel at **35%** for in-office use.

THE MOST PRACTICAL, SAFE AND COMPLETE AUTO-MIXING WHITENING GELS

- Auto-mixing system
- Application of up to 50 minutes without gel replacement
- Contains calcium
- With heat blocker

LEARN MORE ABOUT THE **AUTO-MIXING WHITENING GELS QR CODE**

OVER **6.000** WHITENING SESSIONS WITH **Whiteness** PER DAY ALL AROUND THE WORLD.


FGM
DENTAL GROUP
35%
Whiteness HP Automixx
5g
"With Whiteness HP Automixx I have the exact amount I need for each whitening session; I mix the phases right before the procedure and have total control of it. I prefer to do the upper arch first, then the lower arch. I feel safe because it has a neutral pH, I can leave it on for up to 50 minutes. For me it is one of the most practical whitening gels available.
Dr. Javier Lema
Oral Rehabilitation Specialist
Master in Dentistry
Ecuador

22-year-old female patient.

CHIEF COMPLAINT:
Dissatisfaction with the form of the upper anterior teeth, the asymmetry between the central teeth, and the lateral teeth being too short in relation to the central teeth.

DIRECT VENEERS IN COMPOSITE: FAILURES AND SUCCESSES IN SHADE SELECTION

Authors: **Dr. Gabriela Romanini Basso, Dr. Paulo Gabriel Warmling and Dr. Shizuma Shibata**

INITIAL ASSESSMENT

After detailed anamnesis and clinical examination, it was observed that element 21 was slightly smaller than element 11 and elements 12 and 22 at a discrepancy with the size of the central teeth.

TREATMENT PERFORMED

After the performance of the initial clinical examination, an extraoral and intraoral photo protocol was carried out. The photos and the plaster models were used for the esthetic and functional planning of the case. Once the digital planning was approved, the models were printed, and a palatal guide was manufactured for performing the restorations.

The shade selection was done beforehand with the Vita shade guide and later with composite increments over the tooth structure, and, with the teeth hydrated, the

selected composites were tested. In this case, at first, test increments of the *FGM* **Vittra APS** DAO composite were placed to reproduce the dentin layer and *FGM* **Vittra APS** E-Bleach for reproducing the enamel layer over the vestibular of the central incisors without adhesive treatment. However, in this shade selection step, the value of the dentin composite was not equivalent to the value of the tooth structure, staying overly "lighter" or with a higher value than the natural tooth, so it was necessary to check it again. The thickness of the test increment of the DAO composite was reduced, and the shade/value of the composite was rechecked, confirming that often the thickness of the resin layers is more important in the failure or success of the restoration than the shade itself.


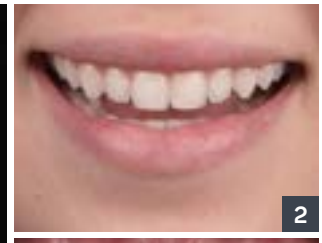


Fig. 1 Initial face photos. | **Fig. 2** Initial smile photo. | **Fig. 3** Initial intraoral photo. | **Fig. 4** Initial photo with a dark background. | **Fig. 5** Mockup for the approval of the project.

Once the composite masses and thicknesses were selected, the modified isolation and removal of the composite remnants from the orthodontic brackets were performed, followed by thorough prophylaxis. The restorations were performed in an additive manner, i.e., no type of preparation was performed, only blasting with 50 µm aluminum oxide to remove the aprismatic enamel with the purpose of optimizing the adhesion.

The total acid etching was performed with the application of 37% phosphoric acid (*FGM* **Condac 37**) for 15 seconds on enamel, protecting the adjacent teeth with a PTFE (non-sintered polytetrafluoroethylene) resin-based tape; right after, rinsing was carried out for twice as long with a water jet and drying with an air jet. The adhesive system used was *FGM* **Ambar APS**, and the application was done with a extrafine **Cavibrush**. A thin layer was applied over the entire etched surface actively for 10 seconds and right after a light air jet for approximately 10 seconds for the evaporation of the solvent, and a second application was performed, followed by photoactivation for 10 seconds.

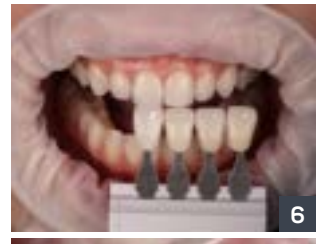



Fig. 6 Shade selection with the guide. | **Figs.7a 7b and 7c** Shade selection with the composite masses. | **Fig. 8** Relative isolation.

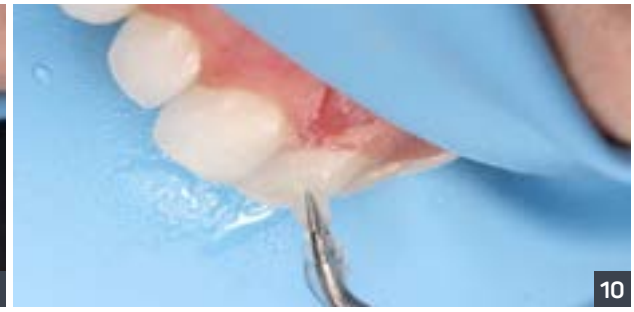

Fig. 9 Prophylactic strip for interproximals. | **Fig. 10** Cleaning with ultrasonic tips. | **Fig. 11** Ultraviolet light. | **Fig. 12** Palatal guide.

In the following step, the restorations began by the palatal shells with the *FGM* Vittra APS E-Bleach composite; next, a layer of composite with opacity compatible with the dentin was applied for reproducing the mamelons and masking of the preexisting optical effects with the *FGM* Vittra APS DAO composite, reproducing the mamelons, respecting the translucency area. For reproducing the incisal halo, a white dye was used only on the incisal edge, and the *FGM* Trans OPL and blue pigment were used to mimic the natural effects of opalescence and counter-opalescence. As the last layer, a more translucent composite was used, *FGM* Vittra APS E-Bleach. Each composite increment with a 2 mm thickness was photoactivated for 20 seconds and the final photoactivation for 40 seconds.

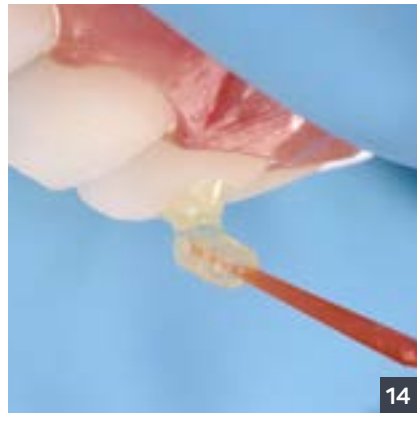

Fig. 13 Conditioning with 37% phosphoric acid (FGM Condac 37). | **Fig. 14** Application of adhesive (FGM Ambar APS). | **Fig. 15** Manufacturing of the palatal shells with the Vittra APS E-Bleach composite (FGM).

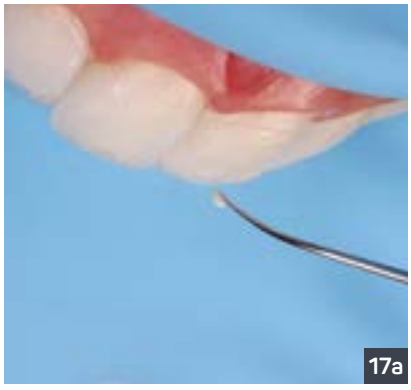

Fig. 16 Making of the mamelons with the Vittra APS DAO resin (FGM)
Figs. 17a and 17b Application of the white dye for reproducing the incisal halo.

Having finished the restorative process and with the isolation removed, the initial finishing step was initiated, which consisted of removing the rough excesses and occlusal adjustment. After 48 hours, we proceeded to the final finishing and polishing, when the mesial and distal marginal ridges were marked, delimiting the light reflection and shade areas. They were regularized with sandpaper disks (*FGM* **Diamond Pro**) from the coarsest to the finest granulation. The polishing was performed with polishers in a spiral format in decreasing granulation; the texture of the grooves was performed with a rubber in a cone format and finalized with felt disks (*FGM* **Diamond Flex**) and polishing paste (*FGM* **Diamond Excel**). The polishing steps were performed with a moist surface, with light pressure of the hand and rotation below 10,000 RPM.

Fig 18 Manufacturing of the last layer with the Vittra APS E-Bleach composite (FGM). | **Fig. 19** Finalized restorations. | **Fig. 20** Photo of the smile before the finishing and polishing steps. | **Fig. 21** Markings of the inclinations and edges to guide the finishing step. | **Fig. 22** Correction of the edges with sandpaper disks of coarser or finer granulation (FGM Diamond Pro).

Figs. 23a, 23b, 23c and 23d Polishing with rubber spirals. **Fig. 24** Last step of the polishing with felt disks (FGM Diamond Flex) and polishing paste (FGM Diamond Excel).

Figs 25a, 25b, 25c and 25d Polishing of the proximal faces with sandpaper straps in decreasing order from the coarsest to the finest granulation. | **Fig. 26** Final intraoral photo.

Fig. 27 Final photos of the patient smiling. | **Fig. 28** Final smile photo. | **Fig. 29** Photo with a dark background.

At the end of the treatment, the teeth presented an aspect of naturality, with shine and smoothness compatible with the natural tooth enamel, meeting the patient's expectations. Hence, it was possible to demonstrate the high mimicry capacity of the composites used. ■

FGM MATERIALS USED

VITTRA APS

Premium composite.

PREMIUM ESTHETICS
EXCELLENT CONSISTENCY
HIGH TECHNOLOGY

APS

ADVANCED POLYMERIZATION SYSTEM

4x

LONGER WORKING TIME UNDER THE REFLECTOR LIGHT

SPHEROIDAL ZIRCONIA SILICATE

High shine and resistance

SHADE STABILITY

The same shade before and after photopolymerization.

*According to study carried out by Prof. Dr. Rodrigo Reis


FGM
DENTAL GROUP
BPA FREE
Learn more about Bisphenol A
TESTED AND APPROVED BY Prof. Dr. Alessandro Loguercio
"A highly innovative composite with unique characteristics.
Prof. Dr. Alessandro Loguercio
Vittra APS
Resina composta fotopolimerizável
light-curing composite resin
2g
FGM

16-year-old female patient.

CHIEF COMPLAINT:
Patient dissatisfied with the color and form of the upper central incisors. The patient reported that she fractured both central teeth as a child. A complicated coronal fracture probably occurred (enamel/dentin fracture involving the pulp).

ANTERIOR ESTHETIC REHABILITATION: **FROM WHITENING TO RECONSTRUCTION WITH VITTRA APS COMPOSITE**

Authors: **Dr. Fabio Cesar Lorenzoni and Dr. Diego Rodrigo Paulillo Bazan**

INITIAL EVALUATION

After a thorough clinical examination, it was observed that these teeth presented alterations in color and shape due to the unsatisfactory restorations. Diastemas between teeth 13/12 and teeth 21/22/23 were also observed. The occlusion evaluation revealed that the patient presents a Dental Class II occlusal relation that will be treated orthodontically. The radiographic evaluation showed that teeth 11 and 21 present satisfactory endodontic treatment. The treatment plan consisted of endogenous whitening of the devitalized teeth through the association of the walking bleach technique with in-office whitening, followed by coronary reconstruction with **Vittra APS** composite.

TREATMENT PERFORMED

After clinical examination and initial photographic protocol, the pulp chamber resin was removed, and 3 mm of the endodontic filling material was extracted beyond the cement-enamel limit. Later, a cervical cap with a glass ionomer was performed. After, the **Whiteness HP Maxx** whitening gel was applied on both the vestibular face and the interior of the pulp chamber, using a protocol of three applications in the same appointment (with an action time of 15 min for each application). Next, the **Whiteness Super Endo** 37% was palced inside the pulp chamber, and the cavity was restored provisionally with composite. The "walking bleach" protocol was performed in three consecutive sections with 7-day intervals between appointments. At the end of the whitening process, the teeth were provisionally restored, and we waited 10 days before performing the adhesion and coronal reconstruction protocol with composite. Molding with addition silicone was carried out to perform the diagnostic waxing, and, from it, a silicone guide was obtained with the goal of guiding the coronal reconstruction. During shade selection, it was defined that the dentin masses DA2 and DA1 would be employed as reconstruction basis (employing the color desaturation technique). The incisal edge was reconstructed with Trans Opal, and the EB1 enamel was employed to finalize the vestibular surface. After the reconstruction was finalized, the restorations were finished and polished with the **Diamond Master** system after 7 days. ■

STEP-BY-STEP

Fig. 1 Initial extraoral aspect. | **Fig. 2** Initial front close-up view. Check the alteration in shape and color of teeth 11 and 21. | **Fig. 3** Occlusal close-up view of teeth 11 and 21. Check the staining of the restorations. | **Figs. 4a and 4b** Front images presenting the measurement of the clearance of the endodontic filling material. | **Fig. 5** Occlusal view of the cervical cap with a glass ionomer. | **Figs. 6a and 6b** Front view (a) and occlusal view (b) showing the application of the whitening gel to the 35% hydrogen peroxide base Whiteness HP Maxx on the vestibular face and pulp chamber. This step was repeated three times and only in the initial appointment of the whitening. | **Fig. 7** The whitening gel changes color, indicating that it must be replaced.

Fig. 8 Final frontal image of the result of the whitening treatment. This image was obtained 1 week after the end of the endogenous whitening Protocol. 3 applications of the Whiteness Super Endo 37% whitening gel were performed.

Fig. 9 Image of the diagnostic waxing.

Figs. 10a and 10b Colored (a) and black and white (b) front images presenting the shade selection. The chromatic map was structured with the following colors: DA2, DA1, EB1, and Trans Opal.

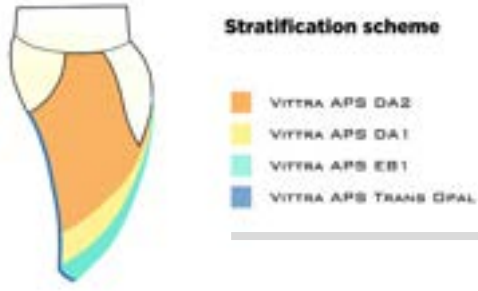

Fig. 11 Illustration representing the stratification scheme of the masses of Vittra APS composite.

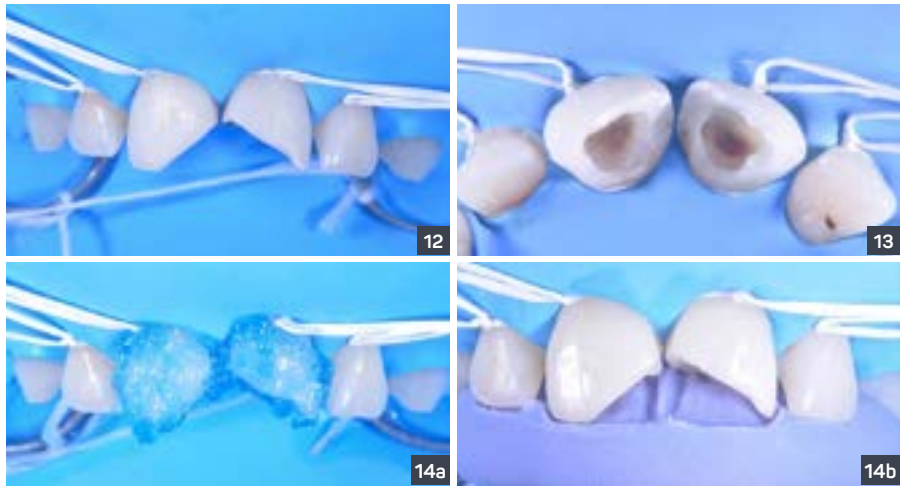

Fig. 12 Frontal image presenting the teeth after the removal of all the composite resin and carious tissue. Absolute isolation is fundamental in such cases.

Fig. 13 Occlusal view where it is possible to observe the size of the cavities to be restored.

Fig. 14 Front images presenting the acid etching with Condac 37% only on enamel (a) and the aspect of the teeth after the application of the APS Universal Ambar Adhesive together with the palatal guide test (b).

Fig. 15 Frontal view presenting the contour of the reconstructions with the Vittra APS Trans Opal composite. | **Fig. 16** Occlusal view of the reconstructions. During the planning, it was chosen to reconstruct the palatal face before beginning the incisor reconstruction. **Fig. 17** Frontal image of the coronal reconstruction with the masses of dentin DA2 (on the base) and DA1 (more superficial). Observe that tooth 11 already presents the stratification of the two masses and tooth 21 only of mass DA2. | **Fig. 18** Frontal image after the stratification of the Vittra APS EB1 resin. | **Fig. 19** Final frontal image right after the stratification process and comfort finish. | **Fig. 20** Intraoral frontal view presenting the planning of the lobes and grooves that are going to determine the texture of the vestibular face. | **Fig. 21** Finalal front image after the finishing and polishing process. Check the shape, texture, and final shade reached. | **Fig. 22** Black and white image where it is possible to observe the texture of the vestibular surface. | **Fig. 23** Final frontal image. The patient was referred to orthodontic treatment to treat the Dental Class II.

FGM MATERIALS USED

FINAL

INITIAL

36-year-old female patient.

CHIEF COMPLAINT:
The patient was dissatisfied with the esthetics of her smile and wanted to close the spaces between the lateral incisive teeth.

ESTHETIC VENEERS IN COMPOSITE
WITH THE VITTRA APS SYSTEM

Authors: **Dr. Orlando Reginatto and Dr. Felipe Pinto Paredes Rodrigues**

INITIAL EVALUATION

After anamneses, clinical and radiographic examinations, the professionals noted the presence of diastemas, inadequate shapes and sizes among the anterior teeth, which were causing patient's dissatisfaction.

TREATMENT PERFORMED

After clinical and radiographic exams, the upper and lower moldings and the occlusal registration were carried out for the digital plan of the case to be produced. After that, the impression of the planned models was requested and then a barrier with addition silicone was made for the mock up to be done and to enable the patient to evaluate the plan.

After the mock up was done and the plan approved, the **PrimmaArt** bis-acryl composite was removed and then the teeth involved in the esthetic treatment were etched with Condac 37 for 15 seconds. The adhesive system used was **Ambar Universal APS**, applied according to the manufacturer's instructions, using a Cavibrush brush.

The veneers in composite were done first using the silicone barrier that was adapted to serve as a guide for the plan. The first layer of composite to be applied was **Vittra APS** in the Trans N shade, in order to achieve the translucent effect of the tooth. Next, in order to make the teeth a little lighter than the initial shade and to reproduce the effects of the characteristics of natural teeth, the shade chosen for this step was DAO of **Vittra APS composite**. As a last layer, to reproduce the features of whitened enamel, the E-Bleach **Vittra APS** composite was applied.

After the composite layers had been placed and correctly photoactivated, in all teeth, by means of **Diamond Pro** sand paper, the sculpting of the grooves was made, creating the areas of light and shadow. With finishing drill bits, the secondary anatomy of the teeth was created, in order to produce an effect of texture and finishing. For the finalization, the polishing was carried out using the **Diamond Flex** disk, with **Diamond Excel** polishing paste. ■

> *"The easy finishing and capacity of polishing of the Vittra APS composite is unparalleled. In young teeth, as in this clinical case, working with a composite that has longevity in terms of shine and polish is essential."*

Dr. Orlando Reginatto
Postgraduate in prosthesis (ABO Florianopolis.
Specialist in Orthodontics (THUM).
Graduate (UFSC).

Fig. 1a Initial aspect. | **Fig. 1b** Close up of the initial smile. | **Fig. 1c** Side view of the initial smile. | **Fig. 1d** Initial contrast. | **Fig. 2a** Face with the mock-up . | **Fig. 2b** Close up view of the mockup smile.

Fig. 3 After prophylaxis, total vestibular and palatal acid etching. | **Fig. 4** Ambar adhesive and polymerization.
Fig. 5a Insertion of the Trans N composite in the matrix. | **Fig. 5b** Palatal shell.

Fig. 6a Insertion of the body of the DAO composite into the incisal face and mamelons. | **Fig. 6b** Incisal design of the restoration body.
Fig. 7a E-bleach 2 external layer. | **Fig. 7b** Finished E-bleach 2 external layer.

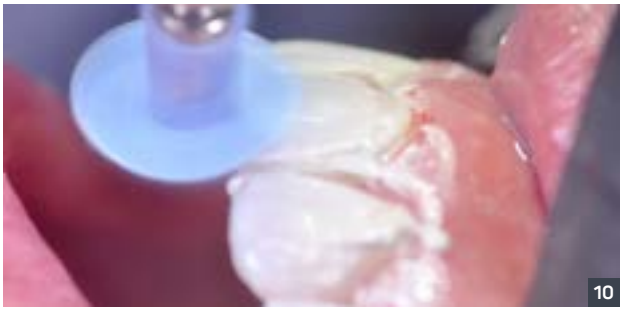

Fig. 8 Sculpting the ridges and determining the light and shadow. | **Fig. 9a** Reference design for secondary anatomy, sulks and textures.
Fig. 9b Sculpting secondary anatomy. | **Fig. 10** Polishing.

Fig. 11a Final aspect.
Fig. 11b Close up of the final smile.
Fig. 11c Side view of the final smile.
Fig. 11d Final contrast.

FGM MATERIALS USED


Vittra
UNIQUE



CHROMATIC MIRRORING COMPOSITES IN DAILY RESTORATIONS

Authors: **Dr. Rodrigo S. Reis and Dr. Michele Vivas**

Restorations in composite account for the majority of the direct restorative procedures carried out in modern clinic. The evolution and the simplification of adhesive techniques and materials, the increase in the efficiency of photoactivation equipment, and, of course, the improvement of composites in terms of esthetic shine and polishing, have made this material the golden standard for applications both in esthetic alterations and transformations and in restorative procedures in anterior and posterior teeth with the highest level of predictability and success.

However, the selection of the shades and the ability of using materials with different degrees of opacity (Enamel, Dentin, Opaque Effect and Translucent Effect, for example) can, frequently, turn a simple procedure into a more complex one when we think of the search for the perfect esthetic mimicking. Even in the simplest daily restorations (Class V, medium and small extensions, Classes I and II), in order to achieve a good shade similitude, the professional must get the right value (luminosity) and chroma (saturation and intensity of the shade) of the shade of the tooth and reach a result that is very close to that shade.

Besides, even being right about all of those, if the professional uses a thickness of enamel that is a little too thick (the most translucent layer), the restoration may become greyish and, likewise, if a layer of dentin is applied a little thicker, with a thinner enamel, an undesirable milky aspect may result.

Due to that, over the last decade there was the introduction of body composites or medium opacity composites, which function as a single composite for those daily restorations. In thicknesses of up to 1.5mm, in average, the optical effect is pleasing (no greyish hues and no milky aspect), however, in thicknesses greater than 1.5mm, it is necessary to use a dentin composite. Even so, in spite of the simplification of the stratification and of the reduction of the error margin in terms of opacity and translucency, shade selection remains a challenge for the professional.

In search of a solution to simplify even more that situation, *FGM* went further: it has developed **Vittra APS Unique**, a composite with medium opacity (body) with chromatic mirroring (monochromatic) which, after being photoactivated, mimics the color of the walls of the cavity preparation and, therefore, with one single composite, the professional can reproduce all the shades. In daily situations such as the ones mentioned above, the shade selection becomes something of the past. Besides simplifying the procedure and allowing the professional to avoid a mistake in the shade of the restoration, it saves you money, since the stock and the need to buy different shades of material become unnecessary for the your daily practice.

Different from the traditional composites which use colored pigments for the obtainment of shade, Unique applies a technology of resin matrixes and balancing of inorganic vitro-ceramic loads whose optical refraction rates are similar to those of the dental structure, a medium opacity degree (prevents greying or a milky look).

Besides that, with the innovative APS system of photo-initiators, the proportion of camphorquinone applied is minimal (compared to all the photoactivated material) and that way, there is no residual yellowing of the shade in the restoration (especially in the lighter and extra lighter shades). As a result, what happens is the real "chameleon effect" that, "like magic" allows for the professional to achieve their goal.

Some points to be considered:

Substrates with non-ideal chromatic aspects (pigmented, darkened) must be neutralized by composite or tint with an opacity effect and receive a layer of dentin in the desired saturation for, then, to receive the Vittra APS Unique (chromatic mirroring composite).

Adhesion well performed, because "gaps" allow for the passage of light and may evidence a margin. Therefore, in any adhesive restoration, the procedure for applying the adhesive must be subject to rigorous criteria. Preferably, we recommend the use of the Ambar APS line – colorless adhesives – if compared to those which have a yellowish hue and may result in a more saturated aspect for the yellow in the restorations with chromatic mirroring.

In very deep cavities, as Vittra APS Unique is a medium opacity composite (body) the results can be optimized with a thin layer of dentin composite (Vittra APS or Opallis for example) in the desired saturation.

For extensive restorations on anterior teeth, Vittra APS Unique can also be applied. However, the area of the missing walls where light goes through, needs to be reconstructed with dentine composite at the desired saturation (to avoid the mirroring effect of the "dark background" of the oral cavity).

Therefore, considering these details which are variations in the dentist's routine, chromatic mirroring composites make the work easier and more economical, besides decreasing the treatment duration (since shade selection becomes unnecessary most of the times) and, with that, restorations of medium and small extensions such as Class V, Class III, Class I and II, besides the reconstruction of disocclusion guides, composite attachments for orthodontic aligners and small incisal angles become easier and more predictable with chromatic mirroring composites such as Vittra APS Unique.

Authors: **Dr. Michele Vivas and Dr. Rodrigo S. Reis**

Michele Vivas is a specialist in Restorative Dentistry and a specialist in Endodontics from São Leopoldo Mandic (RJ), Professor at Instituto R2 Odontologia and Professor at the Specialization Course in Dentistry at São Leopoldo Mandic (RJ).

Rodrigo S. Reis has a doctorate in Dentistry from UFRJ, a master's degree in Restorative Dentistry and Master in Biomaterials from the University of Michigan - USA, specialist in Oral Implantology at UNESA, director of the Instituto R2 Odontologia (RJ) and coordinator of the Specialization in Restorative Dentistry at São Leopoldo Mandic (RJ).

17-year-old male patient.

CHIEF COMPLAINT:
Dissatisfaction with the smile due to the presence of diastema between the upper central incisors.

DIASTEMA CLOSURE
WITH VITTRA APS UNIQUE

Author: **Dr. Carlos Eduardo Agostini Balbinot**

INITIAL EVALUATION

Upon the initial clinical examination, no carious lesions were observed, finding perfect periodontal health of the patient. The presence of a 2 mm diastema between the upper central incisors was observed, with the upper left central incisor slightly inclined in relation to its long axis, but still in a favorable situation for the closure of the diastema. The patient had no complaints about the color of his teeth.

TREATMENT PERFORMED

Prophylaxis with pumice and a restorative test with the **Vittra APS Unique** universal chroma composite were performed, without isolation of the operating field and without previous adhesive procedure. This was done so that the patient could evaluate the intended result relative to both the alteration in shape and color of the restorations. After the patient agreed with the proposed treatment, modified absolute isolation of the operating field was performed, as well as the execution of an adhesive procedure with total acid etching of tooth 21 with 37% phosphoric acid **Condac 37**, application of the **Ambar APS** adhesive system, photopolymerization for 10 seconds, and insertion of the **Vittra APS Unique** composite. After the photopolymerization of the last composite increment used on tooth 21, the finishing was performed with **Diamond Pro** sandpaper disks and polishing with abrasive rubber, a **Diamond Flex** felt disk, and the **Diamond Excel** polishing paste. Once the restoration of tooth 21 was finalized, the restoration of tooth 11 was carried out following the same technical sequence and using pulled polyester matrix strip to obtain a smooth proximal surface and appropriate contact with tooth 21. After the finalization of the restoration of tooth 11, the finishing and polishing procedures were performed, and the patient was scheduled for assessment in 7 days. ■

STEP BY STEP

Fig 1 Initial aspect of the smile. | **Fig 2** Initial intraoral aspect with contrast.
Fig 3 Modified absolute isolation of the operating field.

Fig 4 Protection of the adjacent teeth with TEFLON for performing the adhesive procedure on tooth 21.

Fig 5 Vittra APS Unique before the photopolymerization.

Fig 6 Vittra APS Unique after the photopolymerization. | **Fig 7** Restoration of tooth 21 after finishing with Diamond Pro sandpaper disk.
Fig 8 Tooth 21 after rinsing the 37% phosphoric acid Condac 37 for later application of the Ambar APS adhesive system.

Fig 9 Aspect after the insertion of the Vittra APS Unique composite on tooth 11. | **Fig 10** Immediate intraoral finish with contrast. | **Fig 11** Intraoral finish with contrast after 7 days. | **Fig 12** Final aspect of the smile after 7 days.

FGM MATERIALS USED

20-year-old male patient.

CHIEF COMPLAINT:

Esthetic compromised by diastemas in the upper arch.

ANTERIOR REHABILITATION IN COMPOSITE RESIN
WITH SUBSEQUENT CHANGE OF THE DENTAL SUBSTRATE

Authors: **Dr. Thiago Roberto Gemeli, Dr. Bárbara Robaskievicz and DP Arnã Ariel da Costa**

Several anatomical conditions associated with the size or shape of the teeth can generate esthetic disharmonies and negatively interfere with the socialization and self-esteem of many individuals. The absence of contact between adjacent teeth, a condition known as diastema, is commonly observed between antero-superior elements[1]. The therapeutic approach depends on the diagnosis and can be orthodontic, restorative, or both. Although indirect laminates can also heal this type of condition, the need for dental wear may contradict this

option, especially in the case of young patients and healthy elements[2].

Direct adhesive procedures are an excellent option when well indicated as they are capable of preserving the dental structure and provide excellent esthetic-functional performance[3]. Thus, rehabilitation with composite resins is an important and affordable means to rehabilitate patients with local or generalized diastemas.

CASE REPORT

A 20-year-old male patient attended a private practice complaining mainly of the aesthetic damage associated with the diastemas present in the upper arch. After the anamnesis and initial clinical evaluation, the patient was submitted to complementary photographic/radiographic examinations and archway scanning in order to plan the operative practice.

Because the patient did not want to undergo orthodontic treatment, an exclusively restorative intervention was proposed with an antero-superior six-element approach.

The photographic shots were shared with the laboratory responsible for the digital diagnostic wax-up. The manipulation in software allows editing and sending them to the DP, facilitating communication and allowing them to reach an understanding of what the dentist intends to perform.



Fig. 1 Initial condition of the patient. | **Fig. 2** Initial intra-oral frontal image. | **Fig. 3** Previous elements with reference design for digital wax-up.

After the approval of the project, molding with condensation silicone made it possible to obtain a plaster model. This was scanned and subjected to digital modeling. After final approval, working models were printed and allowed the manufacture of a silicone guide. This facilitates the beginning of the restorative process and the consequent replication of the previously approved anatomical model.



Figs. 4, 5 and 6 Molding and printed model of the previously approved digital waxing and silicone guide to enable replication of the printed design in the mouth.



Fig. 7 Acid etching for 15s of elements 13 to 23 (Condac 37 FGM). | **Fig. 8** Frictional application of adhesive system (Ambar APS FGM). **Fig. 9** Custom silicone guide positioned to assist in the restorative step.

A single resin composite was selected (**Vittra APS Unique** - *FGM*) for this work. Its optical properties favor and optimize mimicry with adjacent tissue structures, an extremely favorable feature for daily clinical practice, as it provides practicality, cost reduction, profitability, and versatility of use.

The use of the **Ambar APS** adhesive seems to be fundamental for the best performance of the composite, as its low camphorquinone load favors mimicry and hardly interferes in the propagation of the color of the substrate to the resinous mass. Another relevant factor to consider is the simplification of the technique, as it dispenses with stratification even in challenging cases.





Figs. 10,11 and 12 Polishing composites with sanding discs (Diamond pro FGM) | **Fig. 13** Instant shade taking | **Fig. 14** Clinical condition after the procedure (A1) | **Fig. 15** Shade taking after 10 days of use of the whitening gel.

After six months of preservation, the patient showed interest in having his teeth whitened, an option discarded by him in the initial approach. Considering the mimetic ability to propagate the color of adjacent walls, the treatment plan included prophylaxis followed by molding to make the custom molds without having to repeat the plastic intervention. The selected gel (**Whiteness Perfect** 10% *FGM*) was recommended for a period of 60 minutes daily for 10 days.

The clinical reassessment showed that the change of color of the substrate by the whitening agent did not impair the final esthetic result of the composite. Unlike what occurs in other resinous systems, the mimetic behavior of the composite used allowed its maintenance in the mouth, not requiring partial or total repairs after the whitening treatment.

This case report is a clear example of how the direct restorative technique with composite resin, when well indicated, is efficient and conservative for closing diastemes, making it an excellent clinical option for the dentist. Another relevant observation is regarding the favorable chameleonic optical behavior of the composite used, which was able to mimic in different optical environments, including when a more significant change in the dentin substrate was promoted (whitening treatment). ■

Figs. 16,17 and18 Comparison between the initial, final, and post-whitening clinical conditions.

REFERENCES

1. **Santos -Pinto, A. dos; Paulin, R.F.; Martins, L.P.** Tratamento de diastema entre incisivos centrais superiores com aparelho fixo combinado a aparelho removível: casos clínicos. J Bras Ortodon Ortop Facial, Cur

2. **Furuse, A.Y.; Franco, E.J.; Mondelli, J.** Esthetic and functional restiration for na anterior relationship wlit multiple diastemata: a multidisciplinary approach. J Prosthet Dent; 99(2): 91-4, 2008.

3. **De Araujo, E,M.JR.; Baratieri, L.N.; Monteiro, S.JR.; Vieira, L.C.; DE Andrada, M.A.** Direct adhesive restoration of anterior teeth: Part2. Clinical protocol. Pract Proced Aesthet Dent. Jun; 15(5): 351-7; quis 9, 2003.

FGM MATERIALS USED

VITTRA APS UNIQUE

Universal chroma composite with the capacity to match the tooth shade.

FROM BLEACH TO D4 WITH ONE COMPOSITE ONLY

APS ADVANCED POLYMERIZATION SYSTEM

THE REAL CHAMELEON EFFECT

BPA FREE

BPA Free composite and syringe

LEARN MORE ABOUT THE VITTRA UNIQUE APS


FGM
DENTAL GROUP
Vitra
UNIQUE
4g
Resina composta fotopolimerizável
unicromática
“ Universal-chroma composite that matches the shade of the dental substrate, brings a sensational esthetic result, combining practicality and quality. In addition to being free of bisphenol A, I also highlight the excellent shine, polish and the practicality when using the incremental technique, which is essential for our specialty.
Prof. Dr. Sandra Kalil
Professor of the subject of dental materials
UNIMES / Santos and UNINOVE / São Paulo

58-year-old female patient.

CHIEF COMPLAINT:

Esthetic discomfort and painful sensitivity when eating frozen food.

RESTORATIVE PROCEDURE OF NON-CARIOUS CERVICAL LESION WITH UNIVERSAL-CHROMA FLOW COMPOSITE

Authors: **Dr. Andreia Luiza Gabriel and Dr. Felipe Pinto Paredes Rodrigues**

INITIAL EVALUATION

After complete anamnesis, during the clinical examination, a non-carious cervical lesion was observed on the vestibular face of element 23, with no presence of dental biofilm and absence of inflammatory process in the surrounding gum tissue. The dentin hypersensitivity (HD) stimulus test performed with air jets showed moderate sensitivity in this region.

TREATMENT PERFORMED

The clinical treatment adopted was the adhesive restoration with **Vittra APS Unique Flow** composite in element 23 in order to reduce the severity of NCL, preventing further losses of the dental structure. The modified absolute isolation of the surgical field was performed due to the easier access to the cervical end of the lesion and the lower chance of gingival injuries. After prophylaxis and insertion of the retraction cord, selective acid etching in enamel was performed with 37% phosphoric acid (**Condac 37**) for 15 seconds.

The application of the **Ambar universal APS** adhesive system was carried out with the aid of a disposable Microapplicator (**Cavibrush**), as indicated by the manufacturer.

The application of the restorative material was carried out by the incremental technique with photoactivation of 20 seconds per increment. After the restoration was completed, the removal of excess composite was done with a fine-grained diamond drill. The finishing and polishing were carried out with the sequence of **Diamond Pro** sanding discs, rubber spirals, and **Diamond Flex** filter disc with **Diamond Excel** diamond paste.

The proposed treatment showed effectiveness in reducing the sensitivity of the dental element. In addition, the restorative procedure provided a decrease in the formation of bacterial biofilm retention areas. ■

STEP BY STEP

Fig. 1 Initial appearance of tooth 23 with non-carious cervical lesion.
Fig. 2 Selective acid etching in enamel with Condac 37 (FGM).
Fig. 3 Application of the Universal Ambar adhesive system APS (FGM) on enamel and dentin.

Fig. 4 Application of Vittra APS Unique Flow compsoite (FGM).
Fig. 5 Aspect of increment before light-curing. Note the white coloring of the composite.
Fig. 6 Aspect of the increment after light-curing, mimicking the color of the tooth.

Fig. 7 Removal of excesses with fine-grained diamond drill.
Fig. 8 Finishing performed with the Diamond Pro (FGM) disc sequence.
Fig. 9 Polishing performed with rubber spirals.

Fig. 10 Polishing performed with rubber spirals.
Fig. 11 Final polishing with diamond Excel diamond paste (FGM) and Diamond Flex felt disc (FGM).
Fig. 12 Final aspect of restoration with Vittra APS Unique Flow (FGM).

FGM MATERIALS USED

L A U N C H

VITTRAAPS UNIQUE FLOW

Universal-chroma flowable light-curing composite with the capacity to match the tooth shade.

THE CHAMELEON EFFECT THAT YOU KNOW WITH THE FLOW THAT YOU NEED

From Bleach to D4 with a single composite

APS ADVANCED POLYMERIZATION SYSTEM

THE REAL CHAMELEON EFFECT

BPA FREE

Bisphenol-A-free composite and syringe.

Check product availability in your country.

AMBAR
ADHESIVE LINE

Light-curing adhesive system for enamel and dentin.

STUDIED AND APPROVED BY SPECIALISTS IN ADHESION

APS ADVANCED POLYMERIZATION SYSTEM

- Superior **adhesive performance** with several levels of **dentin moisture.**
- **More efficient polymerization:** high conversion and adhesion rates.
- **Colorless:** It does not interfere with the esthetics of restorative and cementation procedures.

MDP

Chemical bonding with the dental structure which guarantees long-term adhesive strength.

BPA FREE

PROF. DR. ALESSANDRO LOGUERCIO

MSc in Aesthetic Dentistry, PhD in dental materials. Author of 2 books on the subject. Researcher and professor at the **Univesidade Estadual de Ponta** Grossa. More than **400 articles** published around the world. Cited among the world's top 2% scientists.

24-year-old male patient.

CHIEF COMPLAINT:
Dissatisfaction with the size, format and color of his teeth.

REESTABLISHMENT OF THE BUCCAL CORRIDOR AND SMILE WITH PERIODONTAL PLASTIC SURGERY AND CERAMIC VENEERS

Authors: **Leonardo Fernandes da Cunha, Nayara Couto de Oliveira, Ana Carolina Portes Pasmadjian, Gabriela Resende Allig, Andressa Cristina Motta Nascimento, Clayton Luiz Gorny Junior, and Ubiracy Gaião**

INITIAL EVALUATION

The patient had composite resin restorations of the anterior teeth presenting color alteration and vestibular wear of the resin. He presented chronic gum inflammation between the central incisors due to the old resin closing the diastema. He also presented a difference in gum height between the canines and premolars and height asymmetry between the lateral incisors and canines.

TREATMENT PERFORMED

The prophylaxis and radiographs were performed in the first session. The incisal edge of the anterior teeth was covered by the lower lip while smiling (Figures 1 and 2).

Initially, digital planning was made (Figure 3). With the digital planning presented to the patient, some points were more easily explained and understood by him. Firstly, the need for a periodontal recontour to increase the length of the premolar teeth and the symmetry of the lateral incisors and canines. Second, the need to treat more than six teeth (Figure 4). Hence, the acetate surgical guide was made following the digital planning proposal. The periodontal surgery involving osteotomy was performed. After three months of healing (Figure 5), we opted for the restoration of the teeth employing the indirect adhesive restoration system in a minimally invasive manner. A new waxing was performed, and the mockup to assess the occlusion and form of the teeth was made from it.

The shade selection was made with the Pala shade guide. Next, the resin was removed with disks. After removing the resins, the preparations for the veneers were made with diamond-coated tips 2135 and 3203. A small cervical delimitation was made on the teeth to establish the end of the indirect restorations. For finalizing the preparations, the finishing and polishing of the teeth was performed with diamond-coated tips using a speed multiplier. Initially, the retraction cord 000 and cord 00 were inserted. The molding was performed with addition silicone.

The provisional restorations were manufactured with bis-acryl composite using the previous anatomy of the waxing.

The veneers were made using the ceramic stratification technique, simulating dentin, enamel, and incisal translucency following the waxing guide. The texture with diamond-coated tips was worked, and the glaze was applied (Figures 7 and 8). The restorations were tried on using a try-in paste (*FGM* **Allcem Veneer try-in** E-bleach) for selecting the cement shade. The inner faces of the ceramic restorations were etched with hydrofluoric acid for 60 seconds (*FGM* **Condac Porcelain 5%**). The surface was washed, and the silane agent (*FGM* **Prosil**) and **Ambar APS** adhesive were applied according to the manufacturer's recommendations.

The modified isolation of the operating field and teeth prophylaxis were performed. After protecting the adjacent teeth, the adhesive system (*FGM* **Ambar APS**) was applied to the teeth prepared following the manufacturer's instructions. The cement was applied on the inner face of the restoration and taken in position (*FGM* **Allcem Veneer** E-bleach). The excess cement was removed, and the cement was polymerized for 120 seconds on each tooth.

After cementation, the occlusal contacts were verified and adjusted with a diamond-coated tip. The adjusted areas were polished with rubbers for ceramics.

The final aspect of the restorations, occlusion, and smile may be observed in Figures 10 and 11. ■

STEP-BY-STEP

Figs. 1a and 1b Initial smile of the patient with short premolars.

Fig. 2 Close-up view of the smile. Observe the difference in gum height between the canines and premolars and height asymmetry between the lateral incisors. Also notice the chronic gum inflammation between the central incisors due to the old resin closing the diastema. | **Fig. 3** Digital planning simulating the new gum heights, increase in the vestibular volume of the premolars, and new anatomy for the smile teeth.

Figs. 4a e 4b Close-up view of the model during the planning for the gum recontour of the premolars.

Figs. 5a and 5b Close-up view after the gum recontouring and home teeth whitening | **Fig. 6** After removing the resin with sandpaper disks, the dental preparations and molding with addition silicone were made.

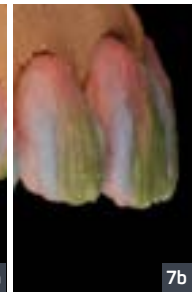

Figs. 7a and 7b Application of the ceramics from the waxed model | **Fig. 8** Finalized restorations after the glaze application. Note the effect to simulate incisal translucency, the definition of the texture, and proximal edges. Treatment for cementation.

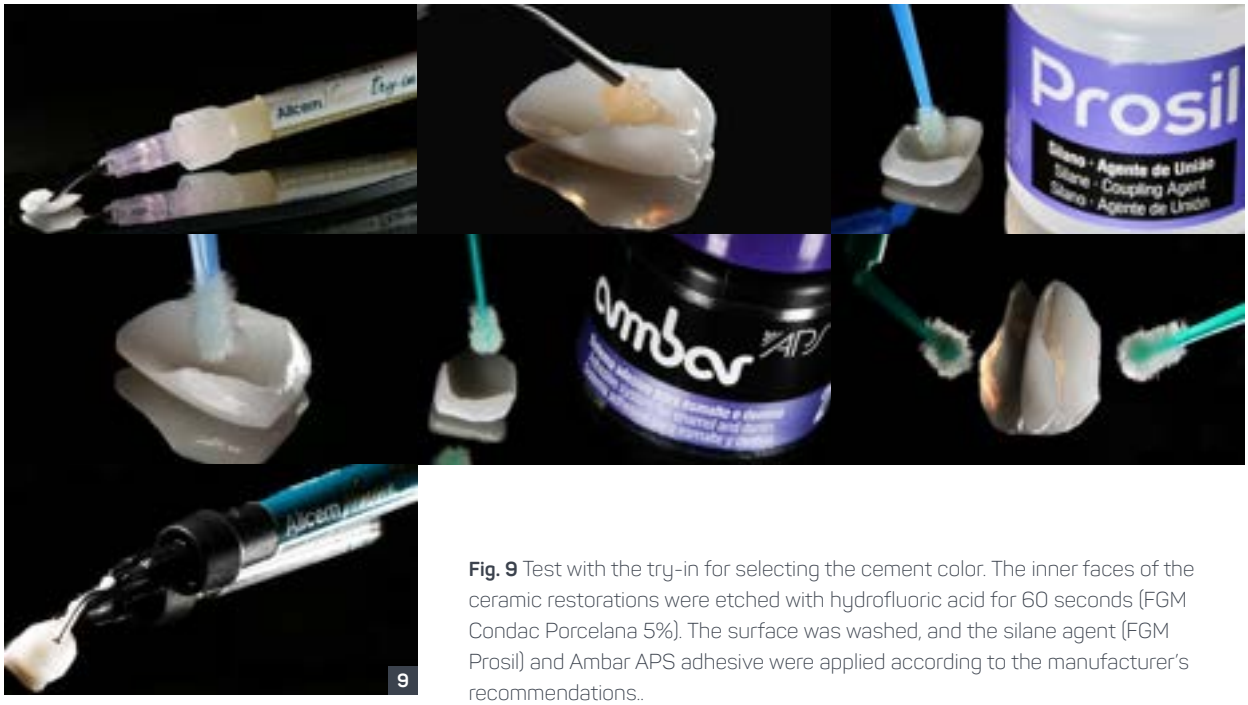

Fig. 9 Test with the try-in for selecting the cement color. The inner faces of the ceramic restorations were etched with hydrofluoric acid for 60 seconds (FGM Condac Porcelana 5%). The surface was washed, and the silane agent (FGM Prosil) and Ambar APS adhesive were applied according to the manufacturer's recommendations..

Figs. 10a and 10b Close-up view of the final restorations after cementation. | **Fig. 11** Final view of the smile reestablishing the buccal corridor and, consequently, the smile aesthetics.

FGM MATERIALS USED

35-year-old female patient.

CHIEF COMPLAINT:
The patient showed dissatisfaction with the esthetics of her smile, specifically with the shape, size, position and color of her teeth.

UPPER AND LOWER ESTHETIC REHABILITATION WITH CERAMIC VENEERS

Authors: **Dr. Felipe Pinto Paredes Rodrigues and DPT. Ariel Arnã da Costa**

INITIAL EVALUATION

After the anamnesis, the clinical and radiographic exams, the professionals noted the presence of dental clusters, teeth of different sizes and inadequate shapes and, also, the need to correct the zeniths of elements 11 and 12 for a better harmonization of the red esthetics.

TREATMENT PERFORMED

After the gingivoplasty of elements 11 and 12, with the purpose of obtaining a better harmony for the red esthetics, intraoral scanning was carried out and, later, the professionals proceeded with the digital planning for the esthetic rehabilitation with lithium disilicate ceramic veneers.

The planning was verified for the upper and lower arches and approved by the patient. In the planning, the proportion of the size of the teeth, the occlusal contacts and the disocclusion guides were evaluated. To make the mockup, the bis-acryl composite PrimmaArt by FGM in the Bleach shade was used.

During the following appointment, the preparations were carried out over the mockup in the upper and lower arches, which has a significant effect for the reduction of the wear of the dental structures, decreasing also the chance of the patient's developing post-treatment sensitivity.

Molding was carried out through the double molding technique with addition silicone and 000 gingival retraction cord. The patient chose the shade of the BL2 ceramics. In order to promote the greatest naturality for the treatment, a veneer with high translucency was selected.

After the dry fitting of the ceramic veneers on both arches, the cement color test was carried out with the use of the Allcem Veneer Try-in paste by FGM in the shades Trans and OW, in order to achieve a greater naturality for the final result. In an agreement with the patient, the selection was for the cement in the shade Trans.

The veneers were etched with Condac Porcelana 10% by FGM for 20 seconds and complemented by the application of Condac 37 by FGM, to neutralize the effect of the hydrofluoric acid, remove the residual vitreous precipitation and increase the contact area of the silane with the ceramics. The silanization was then carried out with the application of Prosil FGM on the internal surface of the veneers.

The teeth were etched through the total acid etching technique with Condac 37 by FGM for 15 seconds, for the conservation of the dental enamel of the preparations. After etching the FGM Ambar Universal APS adhesive was Applied on the surface of the teeth and of the veneers, following the manufacturer's instructions, being volatized for the evaporation of the solvents in order to achieve greater adhesiveness. The cementation was concluded with the planned shade: FGM Allcem Veneer APS Trans.

The result was natural and harmonical, according to the plan. The patient was satisfied and had their self-esteem boosted. ■

STEP BY STEP

Fig. 1 Initial aspect.
Fig. 2 Esthetic plan with PrimmaArt Bleach – mockup.
Fig. 3 Orientation guides – preparation over the mockup.

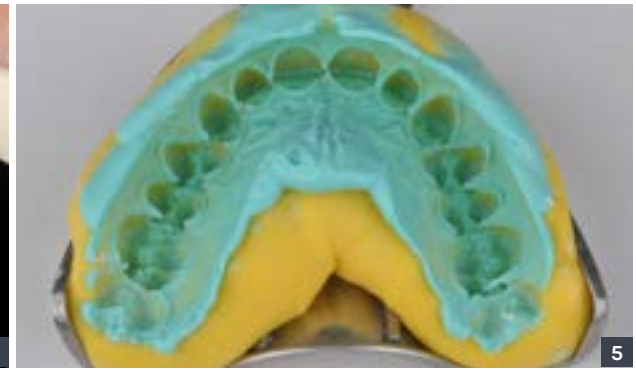

Fig. 4 View of the teeth after the preparation over the mockup. | **Fig. 5** Upper molding in addition silicon.
Figs. 6a, 6b and 6c Ceramic veneers.

Fig. 7 Etching with Condac Porcelana FGM. | **Fig. 8** Application of Condac 37 FGM on the veneers. | **Fig. 9** SSilanization of the veneers with Prosil FGM.

Figs. 10a and 10b After the etching of the teeth with Condac 37 FGM, the Ambar Universal APS FGM adhesive was applied.

11a

11b

Figs. 11a and 11b
Cementation with Allcem Veneer APS Trans FGM.

12

13

14

Fig. 12 Intraoral photograph of the Upper ceramic veneers after cementation.
Fig. 13 Side view of the smile.
Fig. 14 Result.

FGM MATERIALS USED

31-year-old female patient.

CHIEF COMPLAINT:
Dissatisfaction with the size, shade and shape of her teeth.

SMILE HARMONIZATION WITH CERAMIC VENEERS

Authors: **Dr. Lívia Roberta Malpeli Gomes, Dr. Bárbara Elen Lopes Corrêa and DP Mateus Braz**

INITIAL EVALUATION

Initially, the evaluation through anamnesis, complementary clinical exam and radiographies were carried out. A difference between the shape of the central incisive teeth (teeth 11 and 21) was noted, as well as an unleveled gingival contour of the elements 13, 12, 11, 21, 22 and 23. Besides, there were cracks and loss of texture of the dental enamel.

TREATMENT PERFORMED

The treatment proposed to the patient was the periodontal surgery to improve the contour of the clinical crowns of the upper teeth, following the limit of the cement-enamel junction followed by smile harmonization with 10 ultra-thin ceramic laminates to modify the shape, size and color of the dental elements.

Periodontal surgery was performed following the cement-enamel junction with the contour. This way, probing and marking 3 bleeding points was done for each tooth. Thus, it was possible to define the height of the gingival zenith and contour of each clinical crown.

First, the gum of one of the quadrants was removed for comparison effect, which allows for better analysis of the gingival contour of the other quadrant. ■

STEP-BY-STEP

Fig. 1 Initial photo - Smile.
Fig. 2 Initial photo – Intraoral.
Fig. 3 Gingivoplasty – Comparative image between the first and the second quadrants.
Fig. 4 Gingivoplasty – Immediate post-operative aspect. After the surgery, there was an interval of 60 days before the start of the rehabilitation procedure.
Fig. 5 Gingival aspect after the healing period.

After the healing, the preparation of the ceramic veneers was done over the mock-up to control the thickness of the abrasion. However, for teeth 11 and 21, for having different shapes, it was necessary to eliminate the point of contact between them and between them and their adjacent teeth for the professional to be able to modify their shape, improving their symmetry.

Fig. 6 Definition of the end of the preparation and making of the grooves with number 1012 spheric drill to guide the thickness of the abrasion of the dental element.

Fig. 7 Removing the contact point between elements 11 and 21 and rounding of the sharp edges with FGM's sandpaper disk Diamond Pro for there not to be any interference in the ceramic veneer's insertion axle.
Fig. 8 Rounding of the sharp angles of all the elements prepared with sandpaper disk Diamond Pro (FGM).

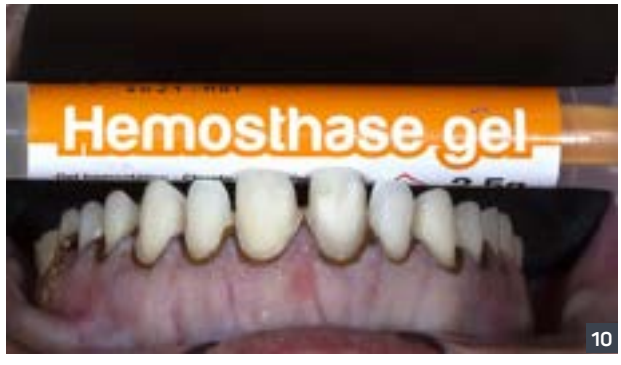

Fig. 9 Final aspect of the prepared elements. | **Fig. 10** Gingival retraction with the help of two retractor cords soaked in Hemosthase Gel (FGM), for the molding. The first cord inserted has a smaller diameter than the second one. | **Fig. 11** Temporary pieces in bis-acryl composite – during the fabrication of the ceramic veneersby the DP, temporary pieces made with PrimmaArt FGM bis-acryl composite in the B1 shade were installed.

Fig. 12 Fitting of the ceramic veneers – checking the fit through the whole extension of the preparation, as well as the selection of the shade of the cement. The product selected was Allcem Veneer Try-in (FGM) in the shade E-Bleach M. | **Fig. 13** Acid etching of the ceramic veneers with Condac Porcelana 5% (FGM) hydrofluoric acid, for 20 seconds. Next, the residue of the etching of the pieces was removed with 70% alcohol. After drying, the silane agent **Prosil** (*FGM*) was applied followed by the Ambar APS (FGM) adhesive system. | **Fig. 14** Acid etching of the preparations with Condac 37% (FGM) phosphoric acid, for 15 seconds, followed by abundant washing with water. After drying, the Ambar APS (FGM) adhesive system was applied. | **Fig. 15** Cementation with Allcem Veneer APS (FGM) resin cement in the E-Bleach M shade and light curing for 60 seconds on the face of each element.

Fig. 16 Immediate aspect after cementation.
Fig. 17 Final aspect.

FGM MATERIALS USED

THE IMPORTANCE OF QUALITY AT FGM DENTAL GROUP

The quality control process at FGM is differentiated, specialized and effective.

Images of FGM Whitening Plant. Photos by: Max Schwoelk

Delivering a quality product to our customers requires study, commitment, method and investment. At FGM Dental Group, the sectors involved with product quality and customer service analyze each detail of the process to guarantee costumer satisfaction and deliver the best results.

Besides correcting flaws that may occur in the productive process, the work of the quality control team also results in the prevention of potential flaws. Commercializing high quality products that fulfill the needs and expectations of is an important value for FGM and critical for a company that is the market leader and is expanding its business to new territories.

Quality control in the productive process.

Opposite to what many imagine, quality control is not only at the end of the manufacturing process. In fact, it is present since the beginning, when the product is still in the planning phase, and continues to follow the manufacturing process up to final packaging. For each type of product, there is a methodology to be applied and, for each phase of the productive process, there is a different team to test the product.

"At FGM, all products are 100% tested, some are analyzed one by one and others through sampling", explains Gisela Cristina Nass de Andrade, Manager of Quality Assurance and Process Engineering. Each day, countless tests are applied to guarantee that the final product fulfills its objective. Some of those products, such as implants and bone grafts, need to undergo rigorous control in their critical production phases and, that way, they are tested one by one in several phases of the process.

In the implants sector, dimensional and functional tests are applied with the use of devices and visual control. In the esthetic dentistry sector, among the processes observed by the quality control teams are: density, raw-materials, consistency, color and other physical-chemical characteristics that the materials need to fulfill in order to perform as intended.

Quality control in customer service

In order to guarantee that the product quality fulfills the demand of the customer, the FGM Customer Service Center keeps contact with customers in Brazil and abroad. "All the interactions with customers are recorded in our system, independently from the channel used. We are able to keep track of the information and, in a strategic way, create actions after the analysis of the compilation of the data in order to avoid new demands for a situation already dealt with," explains Katley Smaha Provin Aguilera, coordinator of Customer Service. Besides, the Customer Service Center is always in search of an 100% customer feedback rate, indicating which action was taken in relation to the interaction, guaranteeing that their issue has been followed up and taken care of.

The Customer Service Center also aims at listening to customers, in a preventive and spontaneous way, by means of customer satisfaction surveys, which are carried out monthly for the purchases done directly from FGM (in the case of implants), from the purchase to the usability after a certain period of use. That way, the whole customer experience is monitored. A great advantage of the FGM Customer Service Center is the existence of a team of customer service consultants and analysts who are qualified to provide good service, besides a technical team formed by specialized professional dentists who, besides answering questions, instruct customers on the correct use of the products for better results.

Registrations and certifications

FGM Dental Group has been certified domestically and internationally. Among the main certifications are: Certificação de Boas Práticas de Fabricação (CBPF) – Certification of Manufacturing Best Practices – issued by the Brazilian National Sanitary Agency (Anvisa), which has the purpose of guaranteeing that the processes in the company fulfill the sanitary requirements for the manufacture and commercialization, in the domestic market, of medical products of high and maximum risk. Another certification is the ISO 13485, related to the Quality Management System for medical products, in which FGM Dental Products is certified by the British Standards Institution (BSI), the leader in global certification, assuring the high level of the quality of the manufacturing processes.

Among the certifications of products, what stands out is the European conformity seal (CE). "That certification is very rigorous and encompasses several aspects of the product's life cycle, from the design, to manufacturing to the post-market monitoring", explains Tiago Ribeiro, manager for Regulatory Issues and Quality Management. That certification has been granted to several lines of products manufactured and commercialized by the FGM Dental Group, such as adhesives, composites, cements, Arcsys implants and the Nanosynt biomaterial. From the regulatory point of view, our products have been evaluated by several health authorities throughout the world, in Latin America, Europe, Asia, Africa and in the United States, proving that the products fulfill the safety and efficacy requirements according to the local legislation of each country.

Aiming at the future, **FGM invests in new horizons**

Investments in infrastructure and development of strategies lead the company to expand in new territories.



Innovation, solidity, and commitment are part of the organizational culture of the FGM Dental Group. In 26 years of history, the company has already launched over 400 products in the esthetics, whiteners, biomaterials, prostheses, and implant lines, becoming a reference as a developer of novelties for the dental market.

Founded in 1996 by the couple Friedrich Georg Mittelstädt and Bianca Mittelstädt, FGM is the leader in teeth whitening in Brazil and over 15 countries, with 85% of the whitening market share in Brazil. The constant search for improvement, with investments in research, technology, and innovation, is the main responsible for the high quality and performance of the company's products.

In 2021, the FGM Dental Group took a significant step towards the future with investments in plant enlargement and expansion to new territories. Besides the opening of new markets around the globe, present in over 100 countries spread over Europe, the Middle East, Asia, Latin America, and North America, the group invested in the enlargement and renewal of its physical spaces. 2021 was the kick-off for an even larger and better FGM.

Investments in infrastructure and qualification

To keep up with the current moment of expansion into new markets and countries, the FGM Dental Group recently invested 30 million Brazilian reais in the enlargement of its physical space with the construction of the new FGM Implants factory, which is predicted to be fully operational in 2023, the enlargement of the logistics center, and the revitalization of the Head Office buildings. Another novelty is the inauguration of a concept store for the Implants market, with the opening of the unit in São Paulo (SP, Brazil). The investments aim at better serving the clients and partners of the organization already consolidated in the aesthetic segment of dentistry:

"FGM is in constant growth, and the investments in the company's physical structure meet the moment of expansion, with the insertion of the brand in new countries and markets", comments the CEO, Bianca Mittelstädt.

In 2021, FGM began integrating the program Partners for Excellence (PAEX) of the Dom Cabral Foundation. The program aims to create a business model capable of aligning purpose, strategy, innovation, social impact, and short-, medium-, and long-term results. To FGM, the adoption of the program is an important step for the company to achieve its first future vision, which is to be among the leading global brands in dental solutions. Moreover, there is a rich exchange of experiences and knowledge of the market practices. Around 600 national and international companies are part of the program.

We have conquered the world.

Check out the countries we are in.

Around the world

The global presence of FGM is the result of the company's commitment to research, development of technologies, and international certifications. There are over 100 importer clients, and the goal is to reach 120 countries up to 2025. Recognized worldwide by the quality of its products, the company's expansion in the international sector is the result of the vision established by the couple Friedrich Georg Mittelstädt and Bianca Mittelstädt already at the beginning of the journey, always focused on developing quality products with scientific backing.

Currently, FGM exports approximately 32% of its production, and, among the products exported by the company, whiteners, composites, cements, posts, and adhesives stand out. The main importers are Peru, Colombia, Turkey, Spain, Portugal, France, Mexico, the United Kingdom, Saudi Arabia, and the United States. Many such countries require certifications for the commercialization, such as the CE (European Conformity) and the ISO 13458, besides the approval, for the United States, of the Food and Drug Administration (FDA).

International recognition

All efforts employed in research, innovation, technology development, and quality control generated international recognition for the products of the FGM Dental Group. The teeth whitening gel Whiteness Perfect (Wit Essential, in the United States) was recognized in the United States by the Dental Advisor for three consecutive years. According to the renowned publication, the whitener is effective in what it proposes to do, having a soft and smooth texture, besides good viscosity of the gel. Evaluated by 31 dental surgeons and after 242 applications on patients, the teeth whitener was praised for the great presentation, which contains all the material that a product needs, and for the entire system, characterized as an "excellent option for patients".

Besides the whitening gel, another FGM product received international recognition for its quality in 2021: the resin cement Allcem Veneer APS was pointed out by Reality Ratings, an American publication of excellence that evaluates dental products. The product developed by FGM received a score of 4.3 of the total 5 points, and the following are among the main benefits of Allcem Veneer APS: handling time and good manipulation, consistency, easy cleaning and application, and minimal color alterations.

For the FGM CEO, Bianca Mittelstädt, the recognitions prove that the investments in research and development of the products bring real results for the business. "The recognitions are an important accreditation of the quality and innovation of our products and lead our path to new markets", she states.

Read the full article on our blog

14-year-old female patient.

CHIEF COMPLAINT:

Dissatisfaction with oral estehtics.

COMPLEMENTARY ADHESIVE DEVICES FOR ORTHODONTIC TREATMENT

Authors: **Dr. Thiago Roberto Gemeli, Dr. Bárbara Robaskievicz and Dr. Rafael Cury Cecato**

The correct installation of orthodontic brackets is an important foundation when the purpose is to perform a more accurate treatment in less time. The correct positioning of the parts will allow the orthodontist to obtain dental movements with greater three-dimensional control, favoring the steps of alignment, leveling, and torque.

In addition to the care associated with the positioning itself, it is worth highlighting the importance of other associated procedures that precede gluing, like prophylaxis. Cementing brackets on a contamination-free surface contributes to this purpose and should always be recommended (Fig. 2).

Compliance with the technique required by the adhesive system used makes it possible to achieve better clinical results. Prioritizing the same trademark between bonding agents and resins becomes essential for the orthodontist's

surgical success, especially with regard to increasing the resistance of the tooth/bracket interface.

Another condition to be observed by the orthodontist relates to the use of complementary devices, which are responsible for providing greater comfort and brevity to the orthodontic intervention. For example, composites developed to inhibit the piercing-cutting action of tie wires, stops for disocclusion or occlusion of dental elements, among others.

CASE REPORT

A female patient, 14 years old, attended a private clinic reporting dissatisfaction with oral estehtics. The clinical evaluation showed slight disharmony between the facial sections (brachycephalic pattern). Therefore, the intermaxillary angle was reduced, suggesting a later approach to increase the vertical dimension through the extrusion of dental elements from both arches intraorally. Slight discrepancy promoted by the presence of diastemas and gyroversion in the upper arch, as well as subtle crowding in the lower arch.

Fig. 1 Initial clinical condition.
Fig. 2 Dental prophylaxis with pumice stone prior to orthodontic bonding.

Fig. 3 Application of etching agent (Condac 37) on the enamel for 20 seconds.
Fig. 4 Application of adhesive (Ambar APS) on the vestibular face of element 21.
Fig. 5 Application of resin cement (Orthocem) directly on the bracket mesh.

Fig. 6 Bracket of element 21 being pressed on the dental surface.
Fig. 7 Presence of stops (Ortho Bite) in the upper canines.
Fig. 8 Upon disocclusion, the stops allow the extrusion of the posterior batteries and assist in the vertical control of the treatment.

CLINICAL TIP

Clinical tip 1 – Use a microbrush soaked with **Ambar APS** to accommodate, adapt and sculpt the stop more easily.

Clinical tip 2 – Use **Top comfort** protective resin on accessory devices that have the potential to traumatize adjacent soft tissues.

The use of techniques and inputs that assist in the stability of orthodontic bonding is an important factor to be considered by the orthodontist. Establishing an operative protocol that includes a prophylactic approach, adequate selection and manipulation of the adhesive system as well as providing stop disocclusion are practices that contribute to a faster, more comfortable, and more cost-effective orthodontic treatment. ■

FGM MATERIALS USED

40-year-old female patient.

CHIEF COMPLAINT:

Smile esthetics and difficulty in eating certain foods due to the occlusal contact.

APPLICATION OF VITTRA APS UNIQUE AS AN ESTHETIC ALTERNATIVE **FOR MAKING ATTACHMENTS FOR ORTHODONTIC ALIGNERS**

Authors: **Dr. Manoela Almeida and Dr. Edgard Belladonna**

INITIAL EVALUATION

In the clinical examination, the professionals noted that the patient had occlusal contacts only on the third molar teeth, with occlusal instability and absence of disocclusion guides. During the anamneses, the patient reported having had orthodontic treatment with fixed braces before, for a long time, and that she would not want to do it again, but showed to be receptive to the orthodontic aligners' technique. When informed about the need for attachments, she showed concern about their esthetics.

TREATMENT PERFORMED

Fig. 1 Initial aspect in occlusion.
Figs. 2, 3 and 4 Acid etching.

Fig. 5 Application of the Ambar Universal APS (FGM) adhesive.
Fig. 6 Adhesive photoactivation.

Fig. 7 Filling of the slots with VIttra APS Unique (FGM) composite inside the template after the isolation of the piece with glycerin.

We chose to use the **Vittra APS Unique** composite, since we would be able to mask the color with its chameleon effect. The patient felt more comfortable and assured of the result.

Fig. 8 Insertion of the template in the mouth with the slots properly filled.
Fig. 9 Photoactivation of the composites in the slots.
Fig. 10 Aspect of attachments immediately after template removal.

Fig. 11 Removal of the excess composite with a multiblade bur. | **Fig. 12** Side view. | **Fig.s 13, 14 and 15** Patient's smile with the attachments.

With **Vittra APS Unique** composite, it was possible to camouflage the color of the dental substrate and keep the esthetic naturality of the treatment. Additionally, as the composite has just one shade which is adaptable to different shades, the process is faster and the stock is reduced. Also, it provides high resistance to wear, an important factor in orthodontics, since, in orthodontic treatments with aligners, there is great tension exerted over the attachments when the patient removes the aligners. ■

FGM MATERIALS USED

THE MOST MODERN
DENTISTRY AT YOUR FINGERTIPS.

THE BEST SOLUTIONS FOR **INVISIBLE ALIGNERS** AND DENTAL WHITENING.

FGM DENTAL GROUP

VITTRA APS UNIQUE AND VITTRA APS UNIQUE FLOW

Due to the ability **to match the tooth shade and achieve perfect mimicry**, FGM unicromatic resins are the best alternatives for making **attachments** for invisible orthodontic aligner.

VITTRA APS UNIQUE is ideal for those who opt to work with resins of higher consistency, and VITTRA APS UNIQUE FLOW for those who prefer the flowable ones.

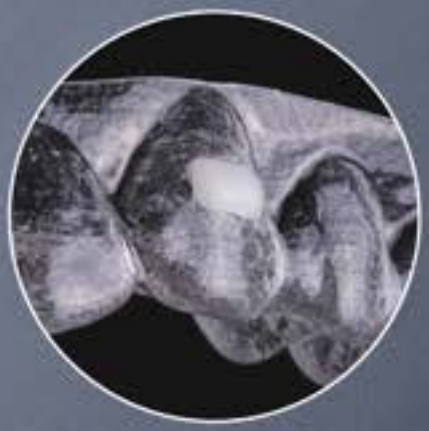

Universal CHROMA Composite

THE REAL CHAMELEON EFFECT

WHITENESS PERFECT

Awarded by **Dental Advisor** as the best take-home whitening gel in the USA for the third consecutive year, Whiteness Perfect can also **be used with the invisible aligner itself** when teeth whitening is combined with orthodontic treatment.